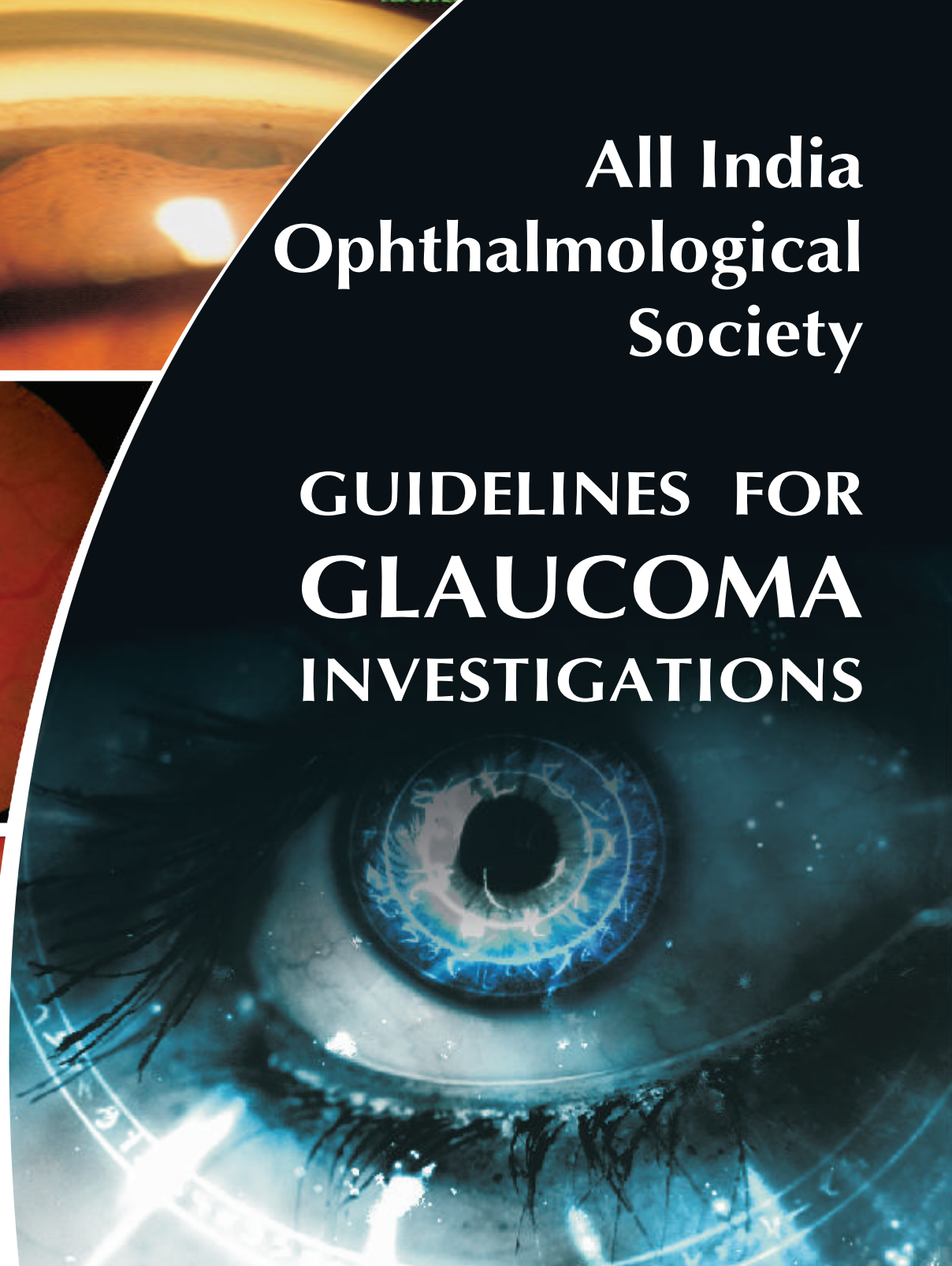




# All India Ophthalmological Society

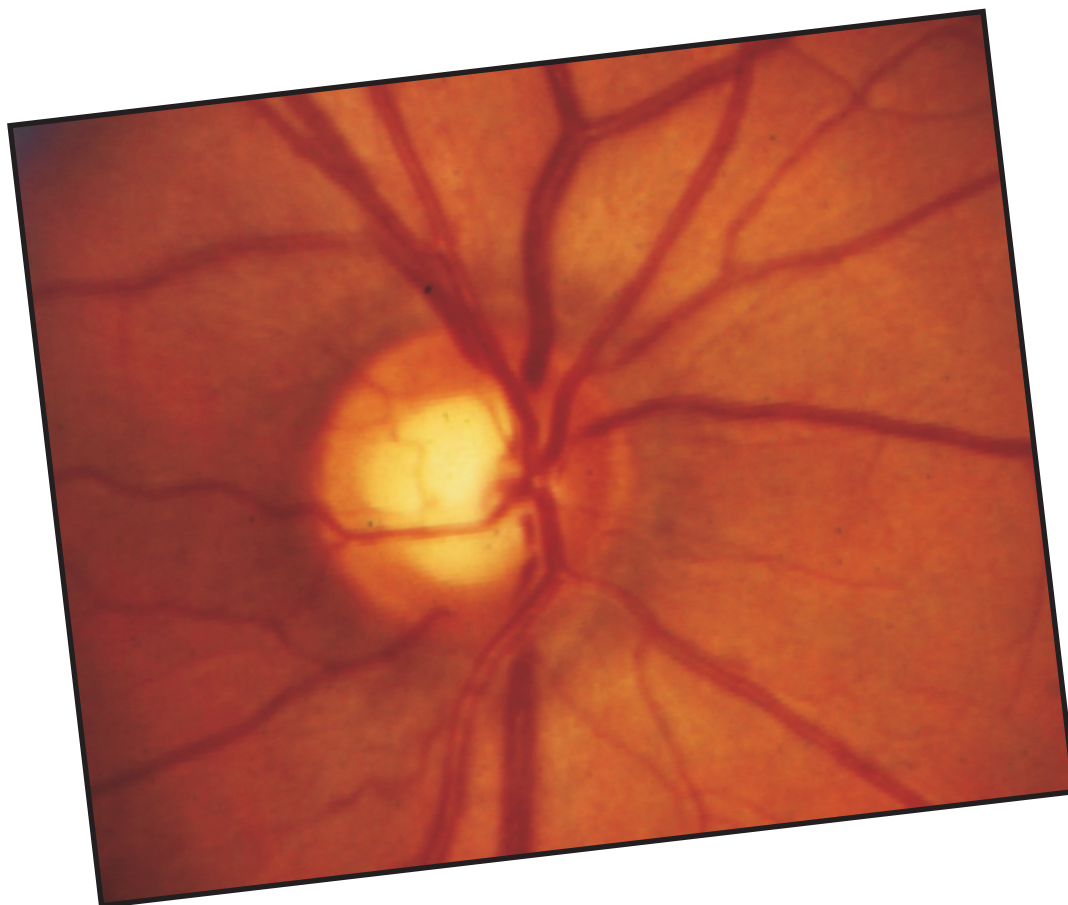
## GUIDELINES FOR GLAUCOMA INVESTIGATIONS



**Joint Initiative of  
All India Ophthalmological Society & Cipla**







*This Document is published by*

**Dr. Lalit Verma**

(Director, Vitreo-Retina Services, Centre for Sight)

Honorary General Secretary, AIOS

## **All India Ophthalmological Society**

Room No. 111, OPD Block

Dr. R.P. Centre, AIIMS, New Delhi-110029 - India

Ph. : 011-26588327

E-mail : [aioffice@yahoo.co.in](mailto:aioffice@yahoo.co.in), [lalitverma@yahoo.com](mailto:lalitverma@yahoo.com)

*For any suggestions please write to*

Hony. General Secretary

AIOS

© Copyright 2012, AIOS.



## **Tanuj Dada**

*Additional Professor*

Dr. Rajendra Prasad Centre for Ophthalmic Sciences  
All India Institute of Medical Sciences, New Delhi

## **Lingam Vijaya**

*Director, Glaucoma Services*  
Sankara Nethralaya, Chennai

## **G Chandra Shekhar**

*Director, L V Prasad Eye Institute*  
Hyderabad

## **Ashok K Khurana**

*Head, Regional institute of Ophthalmology*  
PGIMS, Rohtak

## **S.S. Pandav**

*Head, Glaucoma Services*  
Advanced Eye Centre, PGIMER, Chandigarh

## **P Sathyan**

*Chief, Glaucoma Services*  
Aravind Eye Hospital, Coimbatore

## **Vinay Nangia**

*Director, Suraj Eye Institute*  
Nagpur

## **Sumit Choudhury**

*Senior Consultant, Glaucoma Services*  
Disha Eye Hospital and Research Centre,  
Barrackpore

## **Manish S. Shah**

*Director, Foresight Eye Centre*  
Mumbai

## **Sathi Devi A V**

*Head, Glaucoma Services*  
Narayana Nethralaya, Bangalore

## **Mayuri Khamar**

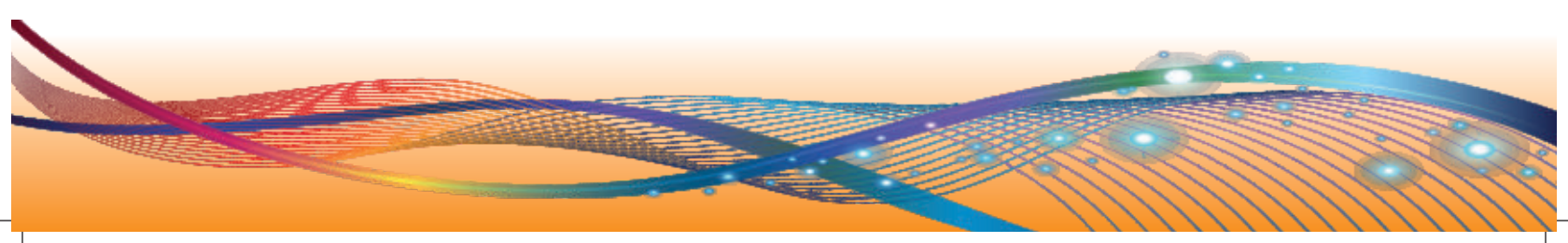
*Glaucoma Centre, Raghudeep Eye Clinic*  
Ahmedabad

## **Jennifer V. Basaiawmoit**

*Medical Director*  
Bansara Eye Care Centre, Shillong, Meghalaya

## **Gursatinder Singh**

*Department of Ophthalmology*  
Government Medical College, Patiala







# *Acknowledgements*

I would like to thank Prof RV Azad, Chief of Dr Rajendra Prasad Centre for Ophthalmic Sciences for his constant encouragement and support. My humble gratitude at the feet of my mentor and guide, Prof. Anita Panda.

I wish to thank Dr Lalit Verma - Hony. Secretary General AIOS, for his dynamic leadership, the compilation of this unique manual on Glaucoma Investigations was his idea. I wish to acknowledge the time and effort put in by my residents - Dr Reetika Sharma, Dr Meenakshi Wadhwani, Dr Amit Sobti, Dr Bhaskar Jha and Mr Ajay Sharma (BSc), the technical officer who maintains the state of art glaucoma facility at our centre.

***Tanuj Dada***

*“Live as if you were to die tomorrow.  
Learn as if you were to live forever.”*

**Mahatama Gandhi**





# Foreword

The use and interpretation of various investigations in Glaucoma is a challenge for most ophthalmologists. We often encounter patients walking into our offices, carrying multiple colour printouts of glaucoma investigations that are difficult to interpret and often don't match clinical findings. Which investigations to use, when to use, how frequently to repeat, etc etc are questions we often face in clinical practice.

This booklet on 'Glaucoma Investigations' is not just another guideline on the subject.

Thirteen lead authors from all zones of the country have written on 13 important and relevant topics related to Glaucoma Investigations – and have included their views, gained over years of experience in the subject.

Written in very lucid and unambiguous language, well illustrated with clinical examples, I hope every Ophthalmologist will benefit from this hard effort put in by Tanuj Dada and co-authors.


I thank all the authors for sparing their valuable time and helping AIOS in bringing out this magnificent book.

I also thank M/s Cipla for their unstinted support for ophthalmic education in the country.

**Dr. R.V. Azad**  
*President (2010-2011)*

**Dr. A.K. Grover**  
*President (2011-2012)*

**Lalit Verma**  
*Hony. Secretary*









# *Editorial*

**G**laucoma is the leading cause of irreversible blindness in India, affecting nearly 12 million people. The main challenge in glaucoma facing our country is that nearly 90% of glaucoma in the community is undetected and there is an inadequate training for making an accurate diagnosis of glaucoma. The current publication under the aegis of the All India Ophthalmological Society (AIOS), is aimed at this unmet need for helping the general ophthalmologist in the diagnosis of glaucoma and imparting education on the judicious use of new technology.

The text covers the basic systemic and ocular diagnostic tests required during the work up of a glaucoma patient such as gonioscopy, intraocular pressure, evaluation of the optic nerve head and standard automated perimetry. In addition this manual includes clinical utility of new tests for structure – GDx, HRT, OCT, UBM with case studies and special techniques of perimetry like SWAP/FDP for early glaucoma detection. The role of imaging in diagnosis and progression of glaucoma is critically reviewed.

The key to making an accurate diagnosis of glaucoma lies in performing a careful gonioscopy to look for irido-trabecular contact and a dilated stereoscopic evaluation of the optic nerve head to pick up early signs of RNFL/Neuro-retinal rim damage. The Goldmann Applanation Tonometer remains the most accurate and reliable instrument for measurement of IOP, however multiple IOP readings are essential to evaluate the timing of peak IOP and also the IOP fluctuation. It is important to perform atleast one test of structure and one test of function at the time of diagnosis and repeat these at follow up visits to look for progression. If expensive instrumentation for evaluating the RNFL/Disc are not available, taking a disc photograph is sufficient. The use of newer tests for structure and function require additional training and should not be used as the sole criteria for diagnosis and initiation of therapy. These tests can be affected by a number of factors such as disc size, nuclear opacification, pupil size, posterior capsule opacification, tear film abnormalities etc and the technician performing these tests has to go through a rigorous training to understand the requisites for capturing a good quality image . If the test results do not match the clinical findings, it is better to repeat the test yourself, rather than rely on the printout given to you. It is important to understand that no instrument can perform better than what your eyes can see and the brain can decipher. However in the hands of the experienced ophthalmologist who knows the advantages and limitations of each technology , clinically useful information can be derived from these tests and put to use for the benefit of the patient.



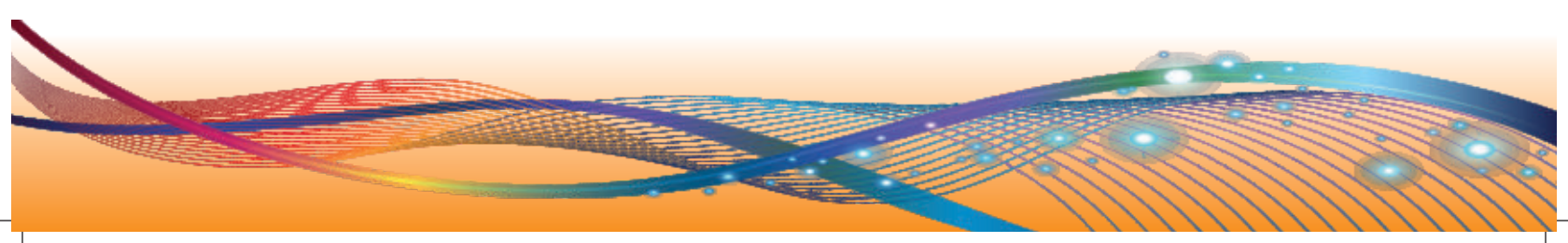


If disc photography is not possible, a diagram of the optic nerve head should be made in the patient file, noting the vertical CD ratio. A diagnosis of glaucoma should not be made on the basis of a single visual field as there is a learning curve while performing standard automated perimetry. At least 2/3 baseline visual fields (Standard Automated Perimetry-SAP) are required and repeat testing may be done at 3/4 month intervals upto 2 years of diagnosis to determine the slope of progression, after which the test may be repeated at 6-12 months intervals depending on the stability of the disease process.

The tests of structure (OCT, GDX, HRT) are required for detection and quantification of Retinal Nerve Fiber Layer (RNFL) loss and Optic Nerve Head (ONH) damage, since RNFL/ONH damage often precedes changes in the visual field and defects on SAP appear after 25-40% of the RNFL has already been damaged. It is important to understand that there is a wide variability in the number of retinal nerve fibers and size/shape of the optic nerve head. Hence if any of these tests detect an abnormality, it just means that the result is outside normal limits of the data base of the particular instrument. In case of an abnormal result, the image quality should be checked and the test should be repeated to check for consistency. A word of caution is advised before interpreting results of these investigations in patients with lenticular opacification as it may lead to under-estimation of the RNFL thickness and it is better to establish a new baseline after cataract surgery. The diagnosis of glaucoma is not made simply by finding an abnormal test but by demonstrating a "progressive change over time" in the RNFL/ONH parameter being evaluated. Early in the course of glaucomatous disease, use of structural tests to document progression is better than functional testing (SAP), while in advanced cases monitoring progression on perimetry is a better option. Another issue which is often debated "Out of these imaging devices which one should I buy?" Although the three instruments (HRT, GDX, OCT) perform equally well in published literature, the Spectral Domain OCT seems to be emerging as the winner as it allows a high resolution imaging of the RNFL, ONH and macula (including the ganglion cell complex), in addition to imaging of the anterior chamber angle and is financially a better option with its use in retinal diseases in a general ophthalmic practice. The tools for anterior segment imaging (ASOCT and UBM) are especially useful for quantification of the anterior chamber angle, imaging in eyes with corneal opacification, evaluation of glaucoma surgery and diagnosis of plateau iris (UBM).

I hope that the practical information provided in this AIOS publication will go a long way in improving the standard of care for glaucoma patients in India and help in alleviating the blindness cause by this "silent killer".

***Tanuj Dada***





# Contents

1.	GONIOSCOPY <i>Tanuj Dada, Vivek Dave, Rajamani Muralidhar</i>	1
2.	TONOMETRY <i>Jennifer V. Basaiawmoit , Tarun Arora, Lt. Col. Dr. Sanjay K. Mishra</i>	12
3.	CORNEAL THICKNESS AND HYSTERESIS <i>Sathi Devi AV</i>	17
4.	EVALUATION OF THE OPTIC NERVE HEAD <i>Sumit Choudhury, Suchanda Sar</i>	24
5.	STANDARD AUTOMATED PERIMETRY <i>SS Pandav, Kanika Aggarwal</i>	29
6.	FREQUENCY DOUBLING AND SHORT WAVE AUTOMATED PERIMETRY <i>Lingam Vijaya, Manish Panday</i>	38
7.	OPTIC DISC PHOTOGRAPHY <i>Manish S Shah</i>	49
8.	CONFOCAL SCANNING LASER TOMOGRAPHY (HRT) <i>Vinay Nangia</i>	52
9.	SCANNING LASER POLARIMETRY (GDX) <i>Mayuri Khamar, Gauri Shah, Vaishali Vasavada</i>	60
10.	OPTICAL COHERENCE TOMOGRAPHY (OCT) <i>P Sathyan, Shilpa B, Anitha S Maiya</i>	67
11.	ULTRASOUND BIOMICROSCOPY AND ANTERIOR SEGMENT OCT <i>Gursatinder Singh, Shalini Mohan, Reetika Sharma</i>	76
12.	SYSTEMIC EVALUATION IN GLAUCOMA PATIENTS <i>Ashok K Khurana, Aruj K Khurana, Bhawna Khurana</i>	80
13.	ROLE OF TECHNOLOGY IN GLAUCOMA DIAGNOSIS AND PROGRESSION <i>G Chandra Shekhar, Harsha Rao</i>	86

# GONIOSCOPY

## Introduction

The term “gonioscopy” is derived from the Greek words *gō'nē* (angle) and *ōs'k-pē* (view). It is a clinical biomicroscopic technique of examining the angle of the anterior chamber of the eye with the use of a special contact lens known as the gonioscope. It was Alexios Trantas in 1907, who first visualized the angle in a living eye, in a case with keratoglobus by indenting the limbus and also coined the term gonioscopy. The Goniolens was introduced by Salzmann, father of Gonioscopy, in 1914 and the Gonioprism by Goldmann in 1938.

## Principle

It is not possible to view the iridocorneal angle of the normal eye directly, because light from the angle strikes the cornea at an angle of incidence  $> 46^\circ$ , which is the critical angle (cornea-air interface) for total internal reflection. Thus light rays coming from the anterior chamber angle exceed this critical angle and are reflected back (Figure 1.1) into the anterior chamber, thereby preventing visualization of the angle. A gonioscope facilitates examination by obviating the air cornea interface (Figure 1.2), thereby allowing light from the angle to exit the eye. Since the index of refraction of the contact lens approaches that of the cornea, there is very little refraction at the interface between these two media, which eliminates the optical effect of the front corneal surface.

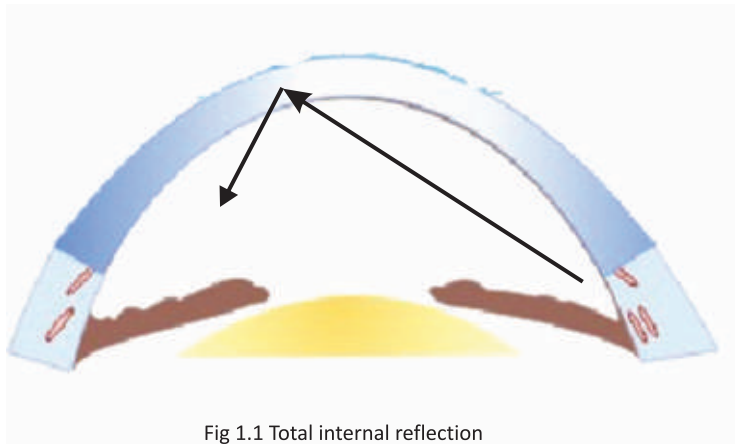


Fig 1.1 Total internal reflection

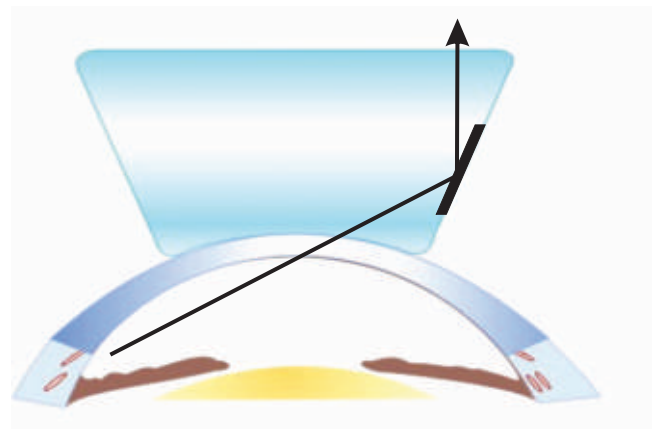


Fig 1.2 Gonioscope over the cornea

## Indications

Gonioscopy is an invaluable tool in diagnosing and planning management for glaucoma cases. The purpose of gonioscopy is to view the drainage system of the eye (trabecular meshwork) and determine the cause for elevated IOP. One of the most common indications for performing gonioscopic examination is to identify angles at risk of closure and distinguish between primary angle closure disease and primary open angle glaucoma. Other critical uses include diagnosis of neovascularization of the angle in eyes with retinal ischemia (eg. CRVO).

Other diagnostic indications include the following (Table 1):

### Table 1 : Indications for Gonioscopy

#### Diagnostic

- Classification of glaucoma – open angle or closed angle
- To assess the anterior chamber angle recess and risk of angle closure



- To identify plateau iris
- To note the presence and extent of neovascularization of angle
- Assessment of abnormal angle pigmentation
- Visualization of pseudoexfoliative material in the angle
- To look for post traumatic angle recession, cyclodialysis
- Rule out foreign body in the angle after open globe injury
- Neoplastic invasion into angle structures (ciliary body tumour)
- Diagnosis of blood in the Schlemm's canal (raised EVP)
- To view copper deposition on Descemet's membrane (KF ring)
- Evaluation of trabeculectomy fistula
- Visualization of glaucoma drainage devices
- To diagnose anterior insertion of iris in developmental glaucoma
- Visualization of congenital anomalies – aniridia, iris processes

### Therapeutic

- Laser trabeculoplasty / goniophotocoagulation
- Goniotomy/gonioplasty/trabectome surgery
- Reopening of a blocked trabeculectomy opening
- Nd-YAG laser after deep sclerectomy
- Laser of suture tied around tube of a glaucoma drainage device
- Indentation gonioscopy to break an acute attack of angle closure

### When to perform gonioscopy?

Gonioscopy should be performed as a part of routine evaluation for all patients visiting an ophthalmologist and is mandatory for all glaucoma patients at diagnosis and during follow up (atleast once a year).

### How to perform gonioscopy?

Gonioscopy is best performed in a dark room with minimal slit lamp illumination and beam height (preferably 1 mm) aimed at the angle, taking care that the slit beam never crosses the pupil and the patient maintains gaze in the primary position. This avoids pupillary constriction which can lead to artificial opening up of the angle in eyes with angle closure. If the angle structures are not visualized, a bright wide slit is used initially at low magnification to identify the angle and then changed to a short-narrow slit. The examiner should wait for atleast 60 seconds for the light induced change in pupillary diameter before commenting on the angle detail. Once the gonioscope is placed view the inferior and superior angle without crossing the pupil, turn the beam 90 degrees and then view the temporal-nasal angle. The observer should see if the posterior pigmented (functional) part of the trabecular meshwork is visible or not. If the posterior part of the trabecular meshwork is not visible, it indicates that there may be irido-trabecular contact (angle closure) and further manipulation/indentation has to be done to view the angle and distinguish between appositional versus synechial closure.

### What to look for during gonioscopy?

While doing gonioscopy the observer should comment on the visibility of the angle structures and report the posterior most structure visible. The following key features should be reported:

1. Scleral spur visible or not
2. The width of the angle recess
3. Level of insertion of the iris

4. Degree of trabecular meshwork pigmentation
5. Shape of the iris
6. Effect of indentation / manipulation on a narrow angle
7. Presence and extent of peripheral anterior synechiae (PAS).
8. Symmetry of gonioscopic findings between the two eyes
9. Other pathologies like neovascularization of the angle, angle recession, silicone oil, foreign bodies, blood reflux in Schlemm's canal etc.

Since the main role of gonioscopy is for the diagnosis of primary angle closure disease, four critical questions need to be answered while performing gonioscopy:

- Q1. Does the iris touch the trabecular meshwork ?
- Q2. Is there any sign of previous irido-trabecular contact (pigmentation)?
- Q3. Is the irido-trabecular contact appositional(reversible) or synechial?
- Q4. What is the extent of circumferential synechial closure?

### The corneal wedge

Identifying the corneal wedge is the key step in defining the angle structures. By using a thin slit of light inclined  $15-20^\circ$  from the angle of the oculars and sharp focus, projected onto the iridocorneal angle, 2 light reflections are noted, one from the external surface of the cornea and the other from the internal surface of the cornea. These two reflections meet at the end of Descemet's membrane which is the beginning of Schwalbe's line (Figure 1.3 -1.5 ). At this landmark the external and internal reflections of the three-dimensional parallelepiped of light merge into a two-dimensional single line with a brighter luminance, which extends in a perpendicular direction across the trabecular meshwork. This method is of great value in lightly pigmented angles and in angles where there is difficulty in identification of normal landmarks or if there is pigment deposition anterior to the Schwalbe's line. However identifying the corneal wedge may be difficult in some cases. By gently sliding the gonioscopy lens in the direction of the mirror being used, the examiner gains a better view of the cornea and the corneal wedge. Locating the wedge is easiest in the superior and inferior angles as it is easy to generate a vertical slit.



Fig 1.3 Corneal Wedge as seen on the slit lamp through the gonioscope




Fig 1.4 The apex of the Corneal wedge meets posterior to the pigmented structure, indicating that this pigmentation is anterior to the Schwalbe's line (not the pigmented trabecular meshwork)






Fig 1.5 Parallelopiped / corneal wedge method of identifying the junction between the external corneal surface (thick light beam) and the internal corneal surface (thin light beam), which marks the Schwalbe's line

### What is an occludable angle ?

If the posterior (pigmented) part of the trabecular meshwork is not visible in more than 180 degrees of the angle, this is known as an occludable angle.

### What type of gonioscope should be used ?

A 4 mirror lens with a diameter less than that of the cornea should be used, so that indentation gonioscopy can be performed . This is mandatory in the diagnosis, classification and management of primary angle closure disease. However the use of a Goldmann type lens gives a better and clear view of the angle structures and facilitates the identification of angle structures, especially during training. A two mirror Goldmann gonioscope is a good , cost effective choice for routine use. The ideal standard for practice is to use both type of lenses (Zeiss type and Goldmann type) as they complement each other.

### How to perform gonioscopy in an eye with a steep iris configuration ?

#### Manipulative Gonioscopy

Manipulation is of value in studying angle anatomy in narrow iridocorneal angles. A more tangential viewing of the angle aids in identification of angle structures obscured by a convex iris. This can be achieved in Goldmann type lenses by simply asking the patient to look in the direction of the mirror or moving the mirror towards the angle being viewed (Figure 1.6- 1.9).

The examiner should report the normal angle view in primary gaze and then document the opening of the angle on manipulation by asking the patient to look into the mirror of the gonioscope, opposite to the angle being examined. For example if you are examining the inferior angle with a Goldmann single mirror gonioscope, the mirror is positioned superiorly. After viewing the angle in primary gaze, you now ask the patient to look upwards, ie. towards the mirror. This allows a better view of the inferior angle as the examiner can look over the iris and into the angle. If the patient looks in the direction opposite of the mirror, the angle appears narrower and vice versa.

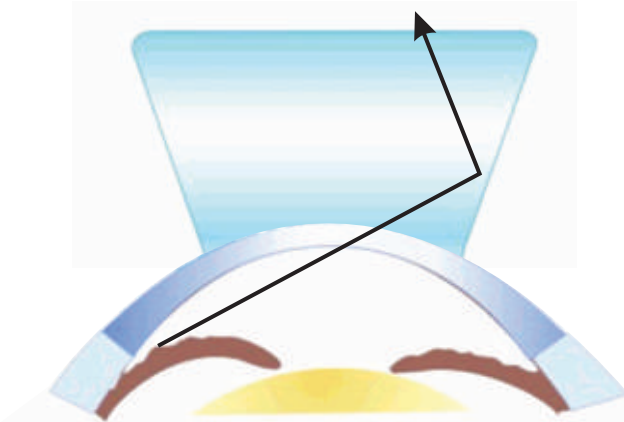


Fig 1.6 A steep iris does not allow view of the angle recess

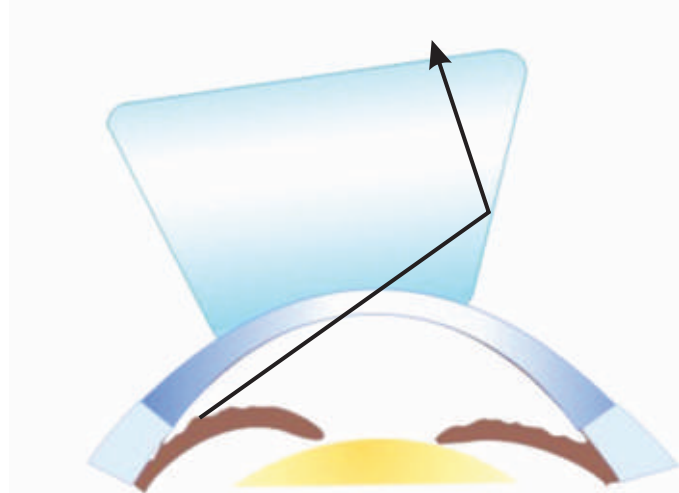


Fig 1.7 Manipulation of Gonioscope towards angle being viewed

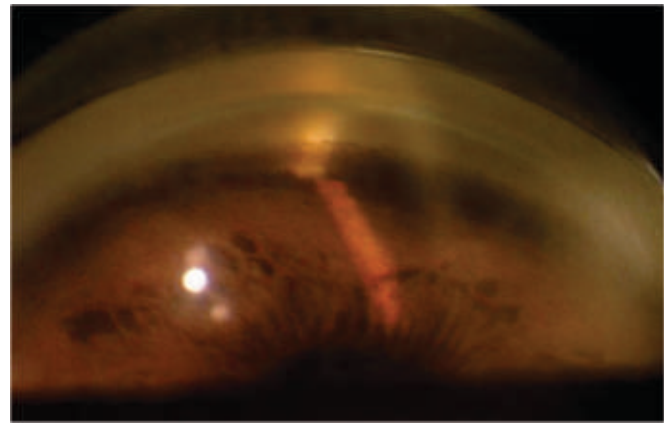
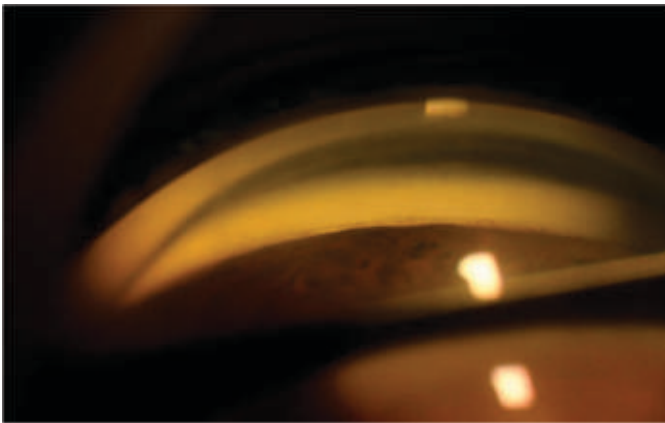


Fig 1.8 -1.9 Closed angle opening on manipulation

This manipulative maneuver can be facilitated by shifting the fixation light, which is positioned in front of the other eye, in the same direction as that of the gonio-mirror being viewed. The examiner can produce a similar effect by moving the lens towards the part of the angle to be examined (eg. By displacing a goniolens inferiorly when examining the inferior quadrant).

Once the goniolens is displaced inferiorly, the superior rim of the goniolens can be used to indent the central cornea and force fluid into the angle thereby opening it. However this technique is cumbersome and indentation gonioscopy using Zeiss type lenses is ideal to confirm degree and type of iridotrabecular contact. The examiner must never apply undue posterior pressure with the Goldmann type lenses as it would lead to a narrowing of the angle as the lens exerts direct pressure at the perilimbal region.

### How to distinguish between appositional vs synechial angle closure ?

#### Indentation Gonioscopy

This type of gonioscopy requires the use of a special type of gonioscopes known as corneal type goniolenses, typified by the Zeiss lens. These have a **9 mm diameter corneal segment** and a **radius of curvature of 7.72 mm** which approximates that of most corneas. This allows the lenses to be used without a coupling fluid, using the

tear film of the cornea. With the corneal type gonioscopes, that have a small diameter, the central cornea may be indented to force the aqueous out and artificially widen the angle. Because the smaller radius of curvature allows these lenses to come into direct contact with the anterior corneal surface, central depression of the cornea will displace aqueous humor peripherally and the iris root posteriorly (Figure 1.10). This technique is also known as *pressure* or *dynamic* gonioscopy. When the iridocorneal angle is optically narrow, indentation gonioscopy also facilitates the identification of angle structures. Should the angle be closed, indentation helps differentiate appositional from synechial angle closure. This is important as synechial closure is irreversible, while appositional closure can be reversed.

When no angle structure is directly visible before indentation, four things can happen on indentation (Figure 1.11):

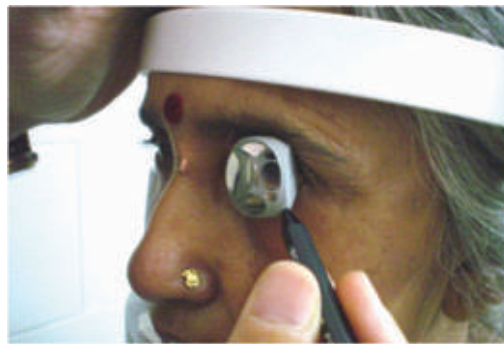


Fig 1.10 Indentation gonioscope placed on cornea

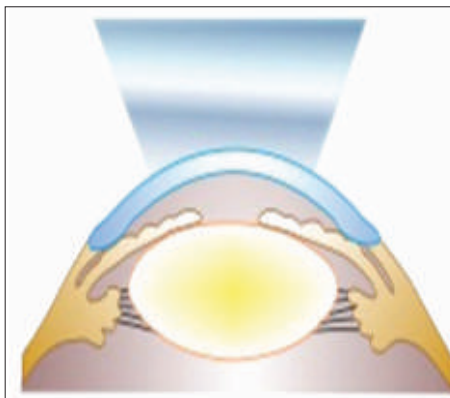


Fig 1.11 Indentation gonioscopy in an apparently closed angle

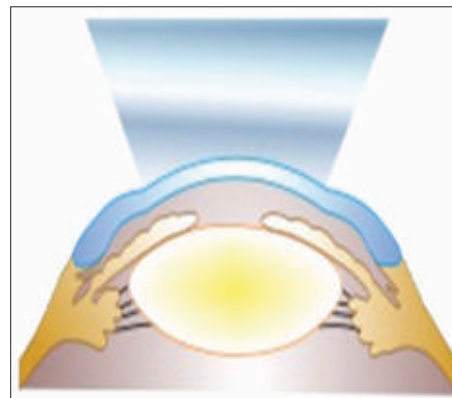


Fig 1.12 If the angle opens up, it was a case with appositional closure

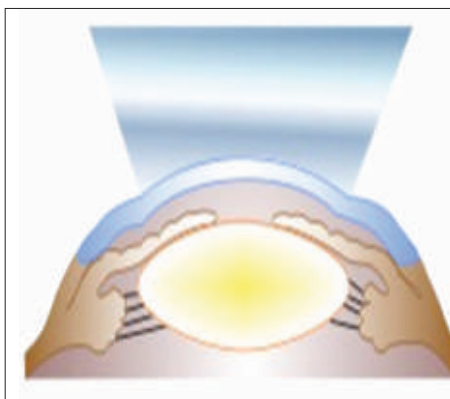


Fig 1.13 If the angle remains closed, indicates synechial angle closure (PAS)

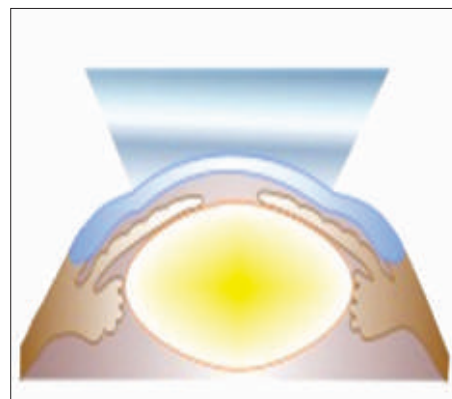


Fig 1.14 A thick lens with no/minimal iris movement

- A) The iris moves peripherally backwards, assumes a concave configuration and the angle recess widens. This represents an appositional closure with a suspicion of a relative pupillary block (Figure 1.12).
- B) The iris moves peripherally backwards, but the periphery of the iris bulges out and does not assume a concave configuration. This represents an anteriorly displaced ciliary body and iris root, typically seen in plateau iris.
- C) The angle widens but iris strands remain attached to the outer wall of the angle. This represents organic synechial closure of the angle (Figure 1.13).
- D) The iris moves only slightly and evenly backward, but retains a convex profile. This can occur due to an anteriorly displaced lens or a large diameter (thick) lens (Figure 1.14).

Indentation gonioscopy with Zeiss type lenses (Posner, Sussman) is the “Gold Standard” for detecting angle closure and differentiating appositional from synechial closure.

### Sterilization and Disinfection of Gonioscopes

Special precautions regarding the disinfection of gonioscopes are mandatory as gonioscopy is a contact investigation which can transfer pathogens from one eye to another. The following steps may be taken to disinfect the gonioscope after use in a patient.

1. Washing the lens on removal with soap and water.
2. Soaking the lens for 5-10 minutes in a fresh solution of diluted sodium hypochlorite (household, bleach:water = 1: 10)
3. Rinsing with sterile water and
4. Air drying the lens.

3% hydrogen peroxide or 1% formaldehyde can also be used as disinfectants. The inside of the gonioscope can be wiped for 10 seconds with a sterile swab soaked in 70% isopropyl alcohol. The sterilization of direct gonioscopes (Koeppel, Swan Jacob etc) used during surgery can be done with ethylene oxide gas sterilization.

### How to depict gonioscopic findings?

There are different classification systems used to grade the angles like Shaffer, Spaeth, Scheie etc but are not practical for routine use. Simply the gonioscopy findings should mention the posterior most structure visible on gonioscopy in the primary position in the superior and inferior angle. Additionally the examiner may comment on the estimate of the angle recess in degrees, iris configuration/ insertion level and degree of pigmentation. Making a diagram of the gonioscopic findings (Goniogram) can help us to compare our findings on serial gonioscopic examinations and is also easy to interpret for other clinicians.

The angle is basically written as superior and inferior angle and the most posterior structure seen. If manipulation/indentation is done, an arrow is put and the structure thus exposed is mentioned (Fig 1.15).

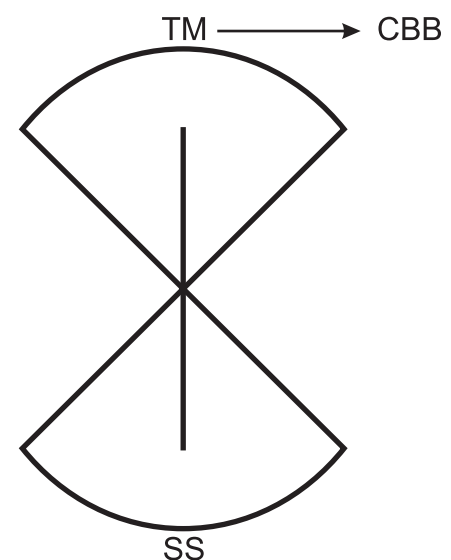


Fig 1.15 Diagram representing angle structures



Another method is to draw a goniogram in the form of 3 concentric circles. The inner circle denotes the scleral spur (SS), middle one is the trabecular meshwork (TM) and outer one is the Schwalbes line (SL). Presence of peripheral anterior synechiae (PAS) or other pathologies like new vessels (NVI) can be drawn in the corresponding clock hour as visible on gonioscopy (Fig 1.16)

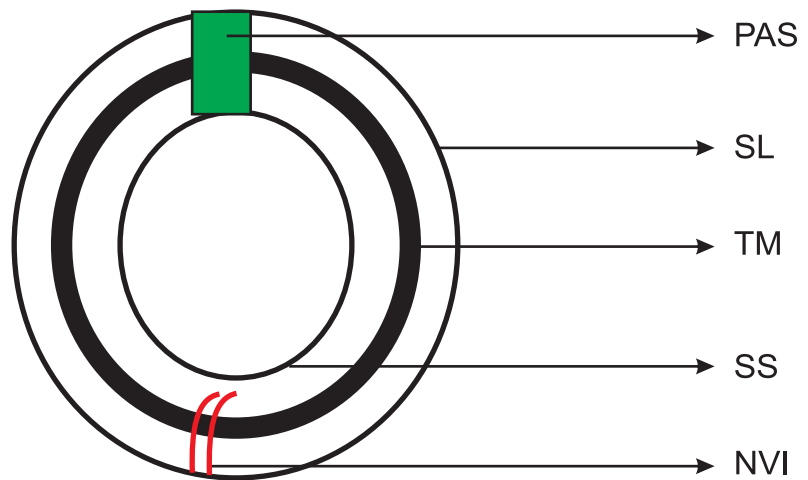



Fig 1.16 Goniogram

### What are the limitations of gonioscopy ?

- Gonioscopy is a contact investigation which causes discomfort to the patient.
- It can transmit a conjunctival infection to the patient.
- Gonioscopy should not be performed in suspected open globe injury or early in the course of closed globe injury with hyphaema as pressure can precipitate re-bleed.
- Gonioscopy is difficult in cases of acute angle closure with corneal oedema and eyes with corneal opacification.
- Excessive pressure while using Goldmann type of lens may artefactually close the angles and while using corneal type of gonioscopes it may give a open angle appearance in narrow recess angle configuration.
- Use of slit lamp illumination while doing gonioscopy leads to pupillary constriction and opens up/changes the angle configuration.
- Gonioscopy cannot objectively quantitate the angle parameters and there is a wide inter-observer variability.
- Gonioscopy is not useful to identify pathologies behind the iris.
- Indentation gonioscopy can lead to formation of corneal folds, distorting the view of angle structures and may cause corneal epithelial injury.
- Mastering gonioscopy has a long learning curve requiring regular practice on a large number of patients.

Gonioscopy remains the “Gold Standard” for evaluation of the anterior chamber angle and should be performed as a basic test like ophthalmoscopy or tonometry. The following section depicts some characteristic gonio-pathologies visible on gonioscopy.



1.17 Closed Angle with no structure visible



1.18 Steep iris configuration with a closed angle




Fig 1.19 Sine wave configuration – Plateau Iris

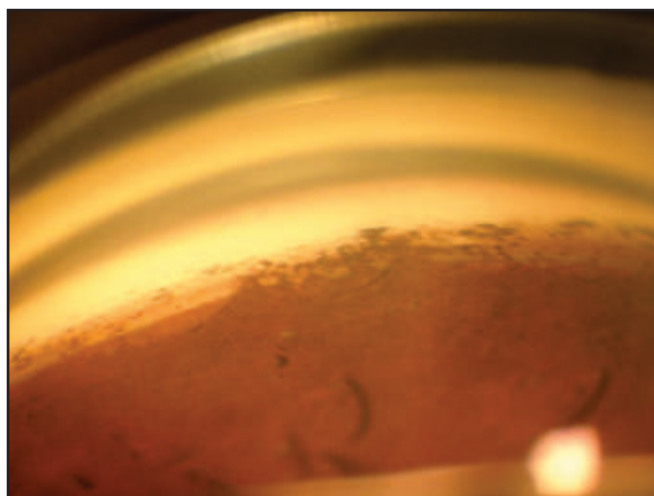


Fig 1.20 Peripheral Anterior Synechiae

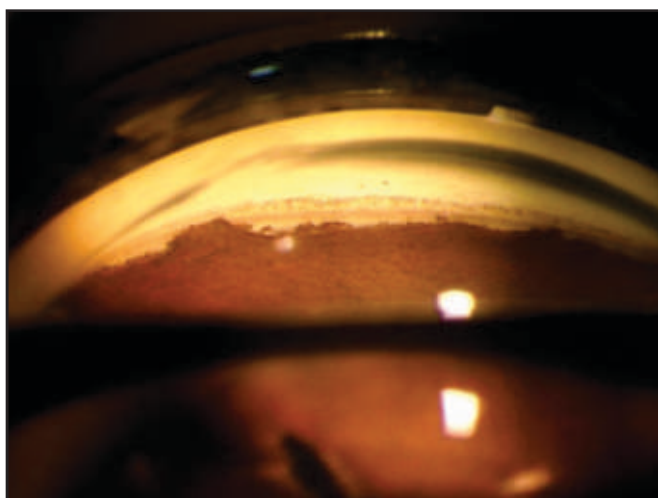


Fig 1.21 Broad based Peripheral Anterior Synechiae




Fig 1.22 Open Angle

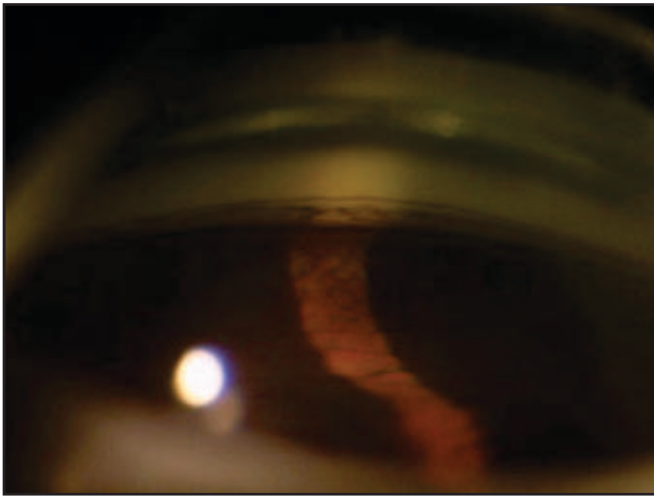
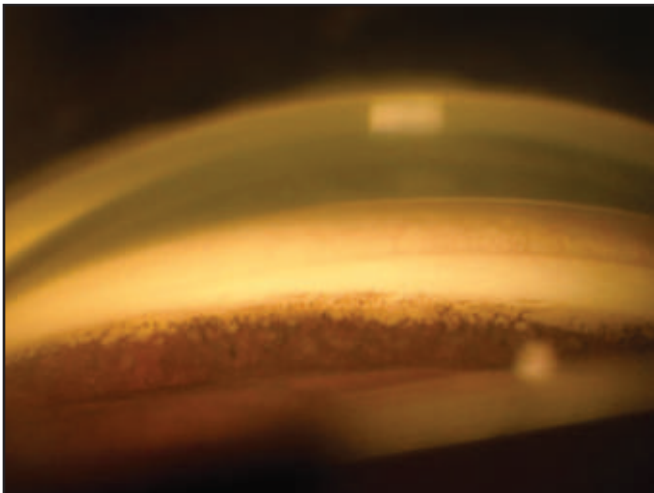


Fig 1.23 Pigment Dispersion Syndrome with Sampaolesi's line



Fig 1.24 Prominent Iris Processes



1.25 Anterior insertion of iris in Juvenile Glaucoma




Fig 1.26 Small iris stump seen in Aniridia



Fig 1.27 Irido-Corneal endothelial (ICE) syndrome



Fig 1.28 Anteriorly displaced Schwalbe's line with irido-corneal adhesions in Axenfeld Reiger syndrome

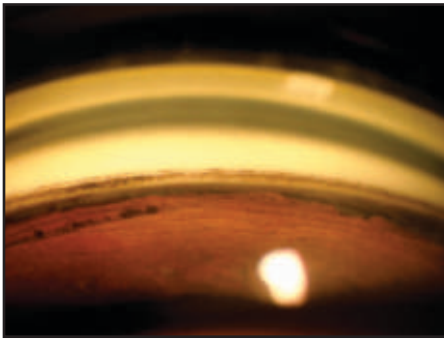


Fig 1.29 Angle Recession with widened ciliary body band

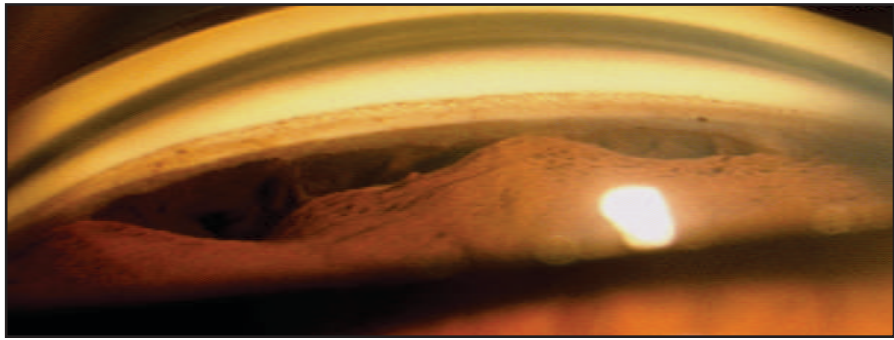


Fig 1.30 Iridodialysis



Fig 1.31 Nodules in the angle in a case of Sarcoidosis

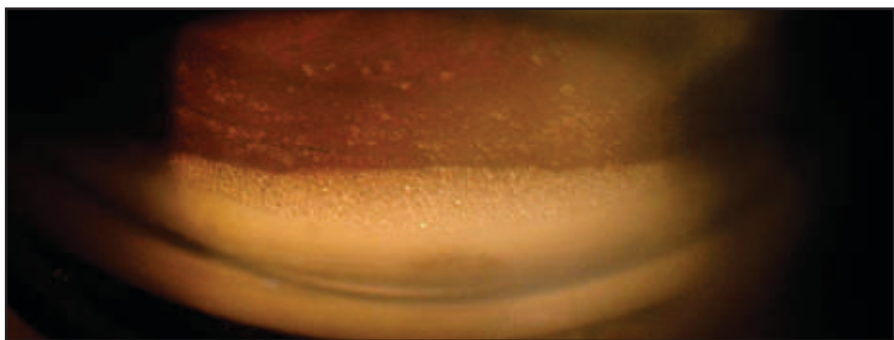


Fig 1.32 Emulsified silicone oil in the angle

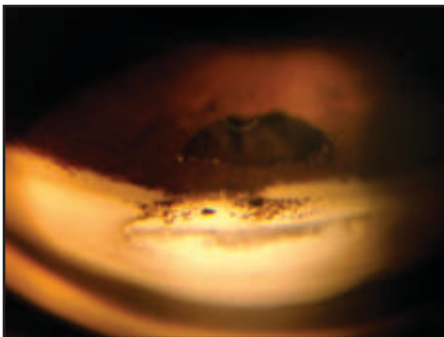


Fig 1.33 Internal ostium of Trabeculectomy




Fig 1.34 Trabeculectomy ostium blocked by iris




Fig 1.35 AGV tube in the angle

### Suggested Reading

Dada T. Gonioscopy : A Text and Atlas. Jaypee Brothers Medical Publishers. 2007. New Delhi

Dada T. Gonioscopy DVD. All India Ophthalmological Society 2011.



# TONOMETRY

Intraocular pressure is a major risk factor in the pathogenesis of glaucoma. Goldmann applanation tonometry is the present gold standard of IOP measurement; however, Goldmann tonometry depends on corneal thickness and on other mechanical parameters of the cornea.

## Goldmann Applanation tonometry:

**History:** It was introduced by Hans Goldmann and Theo Schmidt in 1957.

**Principle:** It works on the principle of Imbert- Ficks Law which states that the pressure in a sphere filled with liquid and surrounded by an infinitely thin membrane is measured by the counter pressure which flattens the membrane or pressure (P) of a body of fluid encapsulated within a sphere is directly proportional to the force (F) required to flatten an area(A) of the sphere.

- However this is true only if the surface encapsulating the fluid is infinitely thin, perfectly elastic, dry, and perfectly flexible and that the only force exerted upon it is from the applanating surface.
- Based on these assumptions, a modification of the Imbert-Fick principle was devised that included factors to consider the resistance of the cornea to applanation and the surface tension of the tear meniscus surrounding the tonometer prism during measurement:

$$W + s = PA + b \text{ (Fig. 1)}$$

Where W = tonometer force; s = surface tension of pre-corneal tear film; P = intraocular pressure; A = area of applanation; b = corneal rigidity/ resistance to bending

- With this formula it was determined that on applanating an external corneal area<sup>1</sup> of approximately 7.35 mm<sup>2</sup>, the effects of corneal rigidity and tear film surface tension forces would cancel. In addition, a force of 0.1 grams would correspond to an IOP of 1 mmHg.

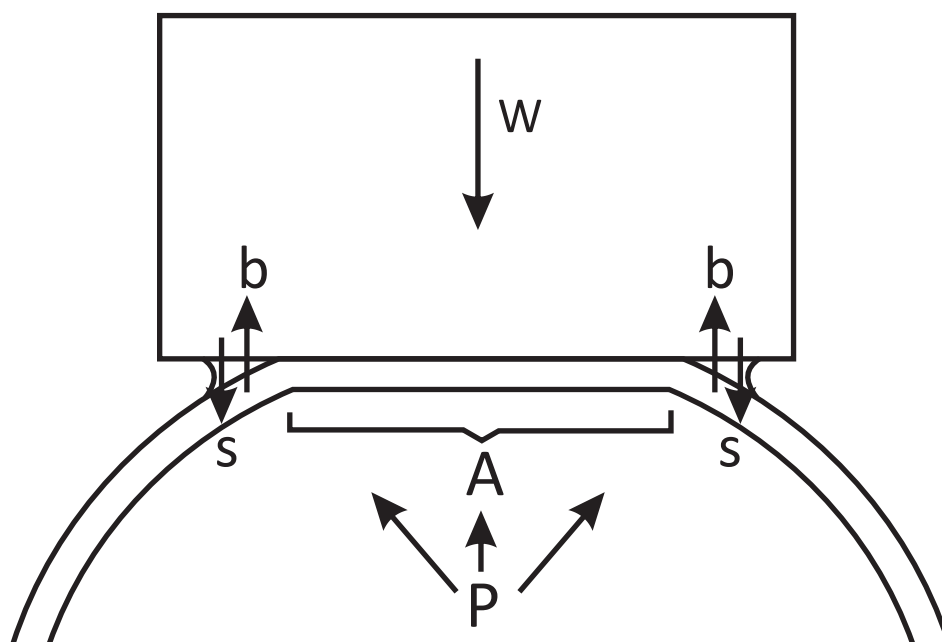


Fig. 1 Representation of forces involved during applanation tonometry. (W = tonometer force; s = surface tension of pre-corneal tear film; P = intraocular pressure; A = area of applanation; b = corneal rigidity/ resistance to bending.)

**Procedure<sup>2</sup>:**

- 1) Instill the local anesthetic drops and then the fluorescein.
- 2) For measuring the IOP in the right eye, make sure the slit beam is shining onto the tonometer head from the patient's right side; for the left eye, the beam should come from the patient's left side.
- 3) Move the filters to produce a blue beam.
- 4) Make sure the beam of light is as wide as possible, and that the light is as bright as possible. This makes visualizing the fluorescein rings easier.
- 5) Ask the patient to look straight ahead, open both eyes wide, fix his or her gaze and keep perfectly still.
- 6) Direct the blue light from the slit lamp onto the prism head.
- 7) Make sure that the tonometer head is perpendicular to the eye.
- 8) Move the tonometer forward slowly until the prism rests gently on the center of the patient's cornea (Fig 2).
- 9) With the other hand, turn the calibrated dial (reading set at zero) on the tonometer upwards until the two fluorescein semi-circles in the prism head are seen to meet and form a horizontal 'S' shape. (Note: the correct end point is when the inner edges of the two fluorescein semi-circle images just touch). (Fig. 3)
- 10) Note the reading on the dial and record it in the notes.
- 11) Withdraw the prism from the corneal surface and wipe its tip.
- 12) Repeat the procedure for the other eye.
- 13) Wipe the prism with a clean, dry swab and replace it in the receptacle containing the disinfectant.



Fig. 2 Prism applanating the corneal surface




Fig. 3 Correct endpoint

### Problems encountered in using the Goldmann tonometer

- The fluorescent band is too wide. This usually occurs if there is a deep tear meniscus or if the lids are in contact with the tonometer head. Dry the tonometer head and start again; otherwise the pressure will be overestimated.
- The fluorescent band is too narrow. The tear film is insufficient. Withdraw the prism and ask the patient to blink several times. A narrow band underestimates the pressure.
- There is a large overlap of the semicircles unresponsive to rotation of the measuring drum. In this case, the tonometer head has been pressed too firmly against the eye. Withdraw the microscope and start again.
- Repeated measurement of intraocular pressure may result in lesions of the corneal epithelium, which will stain with the fluorescein dye. These are rarely severe and cause the patient no distress, although they may cause a little temporary blurring of vision.
- Multiple measurements of intraocular pressure may lead to a gradual reduction in pressure readings due to massaging of the eye (tonographic effect). The first reading in a patient is often higher than repeated second readings, particularly if the patient is anxious and squeezing the eye. If this is the case, the first reading should be discarded.

### Calibration<sup>2</sup>:

- The Goldmann tonometer should be regularly calibrated.
- The calibration arm fits into a slot on the side of the tonometer. The rod is positioned so that the central mark is aligned with the mark on its holder.
- The measuring drum is placed at 0; the pressure arm should gently rock forwards and backwards with slight pressure. Moving the measuring drum between  $-0.5$  and  $+0.5$  mmHg should likewise cause the pressure arm to rock.
- The rod is advanced to the next mark and the process repeated at 20 mmHg and then 60 mmHg (Fig. 4). The tonometer arm should rock between 19.5 mmHg and 20.5 mmHg and 59 mmHg and 61 mmHg respectively. In practice, a slightly greater tolerance may have to be accepted.
- If the calibration is incorrect, the tonometer must be returned to the manufacturer.
- A simple way to test calibration, which should be used at the start of each clinic, is to check that the arm rocks around zero by moving the dial 0.5 mmHg (the width of the calibration mark on the scale) either side of zero with the prism in place.
- Once again, a unit may decide on a slightly higher tolerance. If the tonometer is calibrated at 0 mmHg it is unlikely to be significantly out at 20 and 60 mmHg, although these levels should be checked periodically, as described above.




Fig. 4 Calibration using rod

### Disadvantages:

- Goldmann applanation tonometer cannot be used in case of any corneal abnormality (opacity, irregular cornea, scars).
- It also cannot be used in case of a patient with less co-operation.
- According to a study done by 'Ehlers et al'<sup>3</sup> it has been proved that Goldmann applanation tonometer is reliable only on cornea with central corneal thickness of 520. Goldmann applanation tonometer tends to overestimate pressure in thick cornea and underestimate in thin cornea. Goldmann applanation tonometer tends to overestimate or underestimate IOP by  $\pm 0.71$  mmHg for every  $10\mu\text{m}$  of deviation in corneal thickness.
- Measurement in patients with significant astigmatism<sup>4</sup>
  - The tonometer head is marked in degrees between 0 and 180. If there is less than 3 D of astigmatism, the head is aligned horizontally. That is, the 0° mark is aligned with the white line on the head-holder. If more than 3 D of astigmatism is present the semicircles will be elliptical and the pressure not correctly estimated unless the tonometer head is rotated such that it is positioned at 43° to the meridian of the lowest power. The 43° position is indicated with a red line on the prism housing (Fig.5)




Fig.5 Applanation prism with the red mark.

An alternative technique proposed by Holladay et al. (1983) for regular astigmatism suggests measuring the intraocular pressure with the head in the horizontal position and then at 90° in the vertical position. The two intraocular pressure readings are then averaged. Patients with irregular astigmatism or abnormal corneas may have unreliable intraocular pressure measurements made with the Goldmann tonometer.

### Sterilization:

- Immediate cleaning after use of the tonometer tip with an alcohol soaked sponge, followed by drying<sup>5</sup> for at least 1-2 minutes before next use is recommended.
- More stringent recommendations include cleaning the tip with household bleach. The prism of the tonometer is removed and immersed in a 1:10 solution of household bleach for five minutes. This is followed by washing the tip under running water and dried before next use. The disinfecting solution should be changed at least once daily. Soaking the entire tip may remove the color of the etched calibration marks.
- Soaking the tonometer head for five minutes in 70% isopropyl alcohol may damage the prism of the tonometer.<sup>6</sup>

**Effect of Anesthesia on IOP measurement:** Inhaled and intravenous general anesthetics in widespread use, such as IV propofol and inhaled sevoflurane, rapidly lower IOP within minutes of induction<sup>7</sup>. During an examination under anesthesia, the clinician must measure IOP consistently and early in the anesthetic to gain the most useful clinical information.

**Effect of Posture on IOP measurement:** Posture is an important variable in the measurement of IOP; IOP in the sitting position is generally lower than in the supine position in young healthy adults, in healthy aging individuals, and in untreated open-angle glaucoma patients.<sup>8</sup>



Diurnal fluctuation of IOP: There is strong evidence to support higher mean intraocular pressure (IOP) as a significant risk factor for the development and progression of glaucoma.<sup>9,10</sup> Evidence to support 24-hour IOP fluctuation as a risk factor for glaucoma development or progression is still lacking.<sup>11</sup>

Repeatability of Goldmann applanation tonometry: The studies currently available suggest that measurement precision is greatest with GAT. The repeatability coefficient of Goldmann applanation tonometry is 2.2 to 2.5 mmHg.<sup>12</sup>

Measurement Post Refractive surgeries : Following many forms of keratorefractive surgery, including LASIK, LASEK, and PRK, there is a mean decline in measured IOP using Goldmann tonometry.<sup>13</sup>

### Perkins Tonometer

In some patients positioning at a slit lamp may be impossible because of immobility or because they are under an anesthetic. In these cases a hand-held version Perkin tonometer (Fig. 6) based on the same principle as the Goldmann tonometry can be used.




Fig. 6 Perkins tonometer

New tonometers include Tonopen Avia, Pascal Dynamic Contour Tonometer, Ocular response analyzer, Proview Eye Pressure Monitor and Rebound tonometers (self tonometry for home use), Diaton (through the upper lid) and Non contact tonometry with non contact CCT.

### References

- 1 Goldmann H, Schmidt T. [Applanation tonometry]. *Ophthalmologica* 1957; 134: 221-42.
- 2 Goldmann Applanation Tonometer Instruction Manual. [http://www.newsmaker.ch/upload/customers/haagstreit/Tonometer\\_04091.pdf](http://www.newsmaker.ch/upload/customers/haagstreit/Tonometer_04091.pdf). Accessed 26th May 2007.
- 3 Ehlers N, Bramsen T, Sperling S. Applanation tonometry and central corneal thickness. *Acta Ophthalmol Scand* 1975; 53:34-43
- 4 Holladay JT, Allison ME, Prager TC. Goldmann applanation tonometry in patients with regular corneal astigmatism. *Am J Ophthalmol* 1983; 96: 90-3
- 5 Ophthalmology AAO. Updated recommendations for ophthalmic practice in relation to the human immunodeficiency virus. *Clinical Alert* 2/4. August 1988.
- 6 Key CB, Whitman J. Alcohol soaking damages applanation tonometer heads. *Arch Ophthalmol* 1986; 104: 800.
- 7 Blumberg D, Congdon N, Jampel H, et al. The effects of sevoflurane and ketamine on intraocular pressure in children during examination under anesthesia. *Am J Ophthalmol* 2007; 143: 494-9. Epub 2007.
- 8 Liu JH, Kripke DF, Hoffman RE, et al. Nocturnal elevation of intraocular pressure in young adults. *IOVS* 1998; 39: 2707-12.
- 9 Kass MA, Heuer DK, Higginbotham EJ, et al. The Ocular Hypertension Treatment Study: a randomized trial determines that topical ocular hypotensive medication delays or prevents the onset of primary open-angle glaucoma. *Arch Ophthalmol* 2002; 120: 701-13; discussion 829-30.
- 10 Heijl A, Leske MC, Bengtsson B, et al. Reduction of intraocular pressure and glaucoma progression: results from the Early Manifest Glaucoma Trial. *Arch Ophthalmol* 2002; 120:1268-79
- 11 Liu JH, Zhang X, Kripke DF, Weinreb RN. Twenty-four-hour intraocular pressure pattern associated with early glaucomatous changes. *IOVS* 2003; 44: 1586-90.
- 12 Tonnu PA, Ho T, Sharma K, et al. A comparison of four methods of tonometry: method agreement and interobserver variability. *Br J Ophthalmol* 2005; 89: 847-50.
- 13 Agudelo LM, Molina CA, Alvarez DL. Changes in intraocular pressure after laser in situ keratomileusis for myopia, hyperopia, and astigmatism. *J Refract Surg* 2002; 18: 472-4.

# CENTRAL CORNEAL THICKNESS AND CORNEAL HYSTERESIS

Intraocular Pressure (IOP) has been consistently demonstrated to be associated with incidence, prevalence and progression of glaucoma.<sup>1</sup> Lowering IOP has been shown to reduce the risk of development and progression of glaucoma.<sup>2-4</sup> It is also the most important and only modifiable risk factor in the management of glaucoma. Thus, accurate measurement of IOP is critical.

Goldmann Applanation tonometer(GAT) is currently the standard against which all other tonometers are judged. Goldmann assumed an average corneal thickness of 0.52 mm in designing the tonometer. Excessively thin corneas or thick corneas yield underestimations or overestimations of IOP, respectively, which can lead to erroneous diagnosis of low-pressure or high-pressure glaucoma.<sup>5-8</sup> All forms of tonometry currently available are affected by central corneal thickness(CCT), to a variable extent. Dynamic contour tonometry(DCT) has been shown to accurately measure IOP irrespective of the corneal features because there is minimum applanation. The tip of the tonometer closely matches the corneal contour, thus minimizing the amount of corneal deformation. The effect of CCT on the IOP measured by DCT is about half that of the effect of CCT on GAT IOP measurement.<sup>9</sup> IOPcc measured by the Ocular Response Analyzer(ORA) is also less affected by GAT.<sup>10</sup> Non-contact tonometer(NCT) and rebound tonometry, in which the cornea is indented rapidly, are significantly more affected by CCT.<sup>11,12</sup> CCT accounts for about 1-6% of the variation in GAT IOP and 7-12% of the variation in NCT IOP.<sup>11</sup>

## MEASUREMENT OF CCT

Ultrasonic pachymetry is the current gold standard and most commonly used method for measuring the CCT. This technique has been utilized in OHTS, EGPS, and Barbados Eye study. It entails the use of a probe that makes contact with the cornea and sends out an ultrasound signal that ultimately returns to the probe for analysis of corneal thickness. This technique has been shown to be both accurate and reliable.<sup>13</sup> Since the probe must come into contact with the cornea, local anesthesia is required. Ultrasound measurements can be affected by fluctuations in corneal hydration. Modern methods of optical pachymetry use a camera that takes a series of three-dimensional images of the cornea to calculate the CCT. Measurements with optical pachymetry are generally thinner than with ultrasound. There is no known conversion factor to extrapolate measurements with one technique to a predicted value with ultrasound.

## LIMITATIONS

One of the problems with CCT measurement is whether CCT remains constant over time or whether it changes with age or as a result of the use of topical medications, such as topical carbonic anhydrase inhibitors,(increase CCT) and prostaglandins(decrease CCT).<sup>14</sup> CCT may show diurnal variations with values highest in the mornings and progressively decreasing throughout the day. CCT also varies between racial groups, with values being lower in persons of African<sup>15</sup> and possibly Mongolian<sup>16</sup> descent as compared to Europeans. Other clinic-based studies have not identified significant differences between Asians, Hispanics, and whites.<sup>17,18</sup> The mechanism underlying ethnic differences in CCT is unknown. Twin studies have suggested that CCT is highly heritable.<sup>19</sup> Thus, genetic variation may well account for a significant portion of inter-ethnic variability. The independent association of CCT with DM is consistently found in Singaporean Malay adults<sup>14</sup> and Europeans.<sup>20,21</sup> Possible explanations for this being chronic hyperglycemia adversely affecting corneal endothelial function, an

osmotic gradient drawing fluid into the corneal stroma, or a tendency among diabetics for corneal collagen to develop disulphide cross-linkage.<sup>22</sup> CCT, however, is not associated with refractive error, corneal curvature, anterior chamber depth, or axial length. It is an independent factor unrelated to other ocular parameters.<sup>23,40</sup> However, some studies have identified a positive association between CCT and radius of corneal curvature using optical pachymetry.<sup>24</sup>

### CCT AND GLAUCOMA

The OHTS found CCT to be an important risk factor for progression from ocular hypertension to primary open-angle glaucoma (POAG).<sup>25,26</sup> In a multivariate model that included IOP, CCT was the most powerful component of the predictive model. This finding was validated in the European Glaucoma Prevention Study (EGPS).<sup>27</sup> Each 40 micron of central corneal thinning conferred a 2-fold increased risk for developing glaucoma over 5 years.<sup>28</sup> Despite this result, there is still debate about whether the effect of CCT is through its influence on IOP measurement, through a truly independent expression of risk that is possibly based on biomechanical characteristics of ocular tissues, or both. It is likely that the association of corneal features with glaucoma is more complex than the presence of simple anatomic thickness. No correlation between CCT and lamina cribrosa thickness has been found in nonglaucomatous human eyes.<sup>29</sup> It is not known whether the histomorphometry of the lamina cribrosa or peripapillary nerve fiber layer is correlated with CCT in eyes with glaucoma. This suggests that an assumed relationship between CCT and susceptibility to glaucoma might not be explained by corresponding anatomy between corneal thickness and lamina cribrosa thickness.<sup>29</sup>

In the Early Manifest Glaucoma Trial (EMGT)<sup>30</sup>, recruitment was based on optic nerve and/or visual field changes, not on IOP. No significant association between CCT and glaucoma was found. When patients were followed for 5 years, CCT was not a significant predictive factor for glaucoma progression.

### CLINICAL UTILITY

CCT has been considered a risk factor for glaucoma. A patient with a thicker cornea is thought to have a positive prognosis and a patient with a thinner cornea, a negative one. Several authors have tried to create a formula to establish the "real IOP" by using Goldmann IOP and CCT; however, none succeeded. As yet there is no generally accepted correction formula<sup>31</sup> and the possibility of creating a simple formula applicable to all populations remains uncertain and of questionable clinical relevance. For each 10 mm change in CCT, the change in the IOP reading could range from 0.1 to 0.7 mm Hg.<sup>32-34</sup> Ehlers et al<sup>35</sup> found that GAT most accurately reflected "true" intracameral IOP when CCT was 520µm, and that deviations from this value resulted in an over- or underestimation of IOP by as much as 7 mmHg per 100µm. The implication that IOP can be "corrected" with an arithmetic linear correction factor of a certain millimeters of mercury per micron is an oversimplification of what is undoubtedly a complex and nonlinear relationship between corneal thickness and "true" IOP.<sup>36</sup> The decision to treat a patient with ocular hypertension depends on the assessment of risks, and CCT is an important and necessary part of that determination. On the other hand, if thin central corneas are associated with more advanced glaucoma damage at presentation, clinicians might treat such cases more aggressively, thereby compensating for any added risk from a thin central cornea at that stage in the disease.<sup>37</sup> Several studies have shown that some patients with normal tension glaucoma have thinner corneas than patients with normal eyes.<sup>38,39</sup> Therefore, if CCT is taken into account, these patients may have elevated IOP with "high pressure" glaucoma. This underscores the importance of taking CCT measurements in all patients who have ocular hypertension or glaucoma. A thin central cornea (e.g., 490µm) may explain visual field loss or optic nerve damage in an eye despite normal applanation IOP. Conversely, a thick central cornea (e.g., 610µm) may explain longstanding normal visual field and optic nerve despite a high IOP. However, given the variability in CCT measurements between instruments and the multiple factors that can affect results, it is best to categorize

values as thin, thick, or average instead of using exact numbers in an attempt to classify risk or adjust treatment. Although there are no specifically defined numbers for these various categories, a general guideline would be to categorizing corneas as “thin (<500µm), average (500–600µm), or thick (>600µm).<sup>41</sup>

## SUMMARY

CCT measurement is a necessary part of the evaluation and management of glaucoma suspects and glaucoma patients. All patients with glaucoma or ocular hypertension should have CCT measured at the time of initial diagnosis. Repeating the measurement once in 5 years to be considered as the cornea thins with time. Repeat measurements to be taken after surgeries that compromise the CCT, particularly LASIK (laser assisted in situ keratomileusis). CCT correction factors or nomograms are not recommended as no algorithm can sufficiently adjust for IOP on the basis of CCT alone. Categorizing CCT as thin, average, or thick is best at the present. Other factors such as corneal hydration and viscoelasticity also significantly influence IOP measurements.

## References

1. Kass MA, Heuer DK, Higginbotham EJ, Johnson CA, Keltner JL, Miller JP, Parrish RK, Wilson MR, Gordon MO. The Ocular Hypertension Treatment Study: a randomized trial determines that topical ocular hypotensive medication delays or prevents the onset of primary open angle glaucoma. *Arch Ophthalmol* 2002; 120:701-13.
2. Collaborative Normal-Tension Study Group The effectiveness of intraocular pressure reduction in the treatment of normal-tension glaucoma. *Am J Ophthalmol* 1998;126:498-505.
3. Advanced Glaucoma Intervention Study Investigators. The Advanced Glaucoma Intervention Study (AGIS): 7. The relationship between control of intraocular pressure and visual field deterioration. *Am J Ophthalmol* 2000;130:429-40.
4. Heijl A, Leske MC, Bengtsson B, Hyman L, Bengtsson B, Hussein M; Early Manifest Glaucoma Trial Group. Reduction of intraocular pressure and glaucoma progression: results from the Early Manifest Glaucoma Trial. *Arch Ophthalmol* 2002;120:1268-79.
5. Ehlers N, Hansen FK. Central corneal thickness in low-tension glaucoma. *Acta Ophthalmol (Copenh)* 1974; 52:740–746
6. Johnson M, Kass MA, Moses RA, Grodzki WJ. Increased corneal thickness simulating elevated intraocular pressure. *Arch Ophthalmol* 1978; 96:664–665.
7. Whitacre MM, Stein RA, Hassanein K. The effect of corneal thickness on applanation tonometry. *Am J Ophthalmol* 1993; 115:592–596
8. Herndon LW, Choudhri SA, Cox T, Damji KF, Shields MB, Allingham RR. Central corneal thickness in normal, glaucomatous, and ocular hypertensive eyes. *Arch Ophthalmol* 1997; 115:1137–1141.
9. Kotecha A, White ET, Shewry JM, Garway-Heath DF. The relative effects of corneal thickness and age on Goldmann applanation tonometry and dynamic contour tonometry. *Br J Ophthalmol* 2005; 89:1572-5
10. Medeiros FA, Weinreb RN. Evaluation of the Influence of Corneal Biomechanical Properties on Intraocular Pressure Measurements Using the Ocular Response Analyzer. *J Glaucoma* 2006;15:364-70
11. Tonnu PA, Ho T, Newson T, et al. The influence of central corneal thickness and age on intraocular pressure measured by pneumatonometry, non-contact tonometry, the Tono-Pen XL and Goldmann applanation tonometry. *Br J Ophthalmol* 2005; 89
12. Nakamura M, Darhad U, Tatsumi Y, et al. Agreement of rebound tonometer in measuring intraocular pressure with three types of applanation tonometers. *Am J Ophthalmol* 2006; 142:332-4
13. Doughty MJ, Zaman ML. Human corneal thickness and its impact on intraocular pressure measures: a review and meta-analysis approach. *Surv Ophthalmol* 2000; 44:367–408
14. Shildkrot Y, Liebmann JM, Fabijanczyk B, Tello CA, Ritch R. Central corneal thickness measurement in clinical practice. *J Glaucoma* 2005; 14:331–336
15. Nemesure B, Wu SY, Hennis A, Leske MC. Corneal thickness and intraocular pressure in the Barbados eye studies. *Arch Ophthalmol* 2003;121(2):240–244.
16. Foster PJ, Baasanhu J, Alsibirk PH, Munkhbayar D, Uranchimeg D, Johnson GJ. Central corneal thickness and intraocular pressure in a Mongolian population. *Ophthalmology* 1998;105(6):969–973.
17. Aghaian E, Choe JE, Lin S, Stamper RL. Central corneal thickness of Caucasians, Chinese, Hispanics, Filipinos, African Americans, and Japanese in a glaucoma clinic. *Ophthalmology* 2004;111(12):2211–2219.
18. Yo C, Ariyasu RG. Racial differences in central corneal thickness and refraction among refractive surgery candidates. *J Refract Surg* 2005;21(2):194–197.
19. Zheng Y, Ge J, Huang G, et al. Heritability of central corneal thickness in Chinese: the Guangzhou Twin Eye Study. *Invest Ophthalmol Vis Sci* 2008;49(10):4303–4307.
20. Su DH, Wong TY, Wong WL, et al. Diabetes, hyperglycemia, and central corneal thickness: the Singapore Malay Eye Study. *Ophthalmology* 2008;115(6):964–968.
21. Pfeiffer N, Torri V, Miglier S, Zeyen T, Adamsons I, Cunha-Vaz J. Central corneal thickness in the European Glaucoma Prevention Study. *Ophthalmology* 2007;114(3): 454–459.



22. Simpanya MF, Ansari RR, Suh KI, Leverenz VR, Giblin FJ. Aggregation of lens crystallins in an in vivo hyperbaric oxygen guinea pig model of nuclear cataract: dynamic lightscattering and HPLC analysis. *Invest Ophthalmol Vis Sci* 2005;46(12):4641–4651.
23. Shimmyo M, Orloff PN. Cornea thickness and axial length. *Am J Ophthalmol* 2005; 139:553–554
24. Mishima S, Hedbys BO. Measurement of corneal thickness with the Haag-Streit pachometer. *Arch Ophthalmol* 1968; 80(6):710–713.
25. Gordon MO, Beiser JA, Brandt JD, Heuer DK, Higginbotham EJ, Johnson CA, Keltner JL, Miller JP, Parrish RK II, Wilson MR, Kass MA. The Ocular Hypertension Treatment Study; baseline factors that predict the onset of primary open-angle glaucoma; the Ocular Hypertension Treatment Study Group. *Arch Ophthalmol* 2002; 120:714–720.
26. Palmberg P. Answers from the Ocular Hypertension Treatment Study [editorial]. *Arch Ophthalmol* 2002; 120:829–830
27. European Glaucoma Prevention Study (EGPS) Group. Predictive factors for open-angle glaucoma among patients with ocular hypertension in the European Glaucoma Prevention Study. *Ophthalmology* 2007; 114:3–9
28. Ocular Hypertension Treatment Study Group, European Glaucoma Prevention Study Group. Validated prediction model for the development of primary open-angle glaucoma in individuals with ocular hypertension. *Ophthalmology* 2007; 114:10–19
29. Jonas JB, Holbach L. Central cornea thickness and thickness of the lamina cribrosa in human eyes. *Invest Ophthalmol Vis Sci* 2005; 46:1275–1279.
30. Leske MC, Heijl A, Hussein M, Bengtsson B, Hyman L, Komaroff E. Factors for glaucoma progression and the effect of treatment; the Early Manifest Glaucoma Trial; the Early Manifest Glaucoma Trial Group. *Arch Ophthalmol* 2003; 121:48–56.
31. Brandt JD. Corneal thickness in glaucoma screening, diagnosis, and management. *Curr Opin Ophthalmol* 2004; 15:85–89
32. Doughty MJ, Zaman ML. Human corneal thickness and its impact on intraocular pressure measures: a review and meta-analysis approach. *Surv Ophthalmol* 2000; 44:367–408
33. Kniestedt C, Lin S, Choe J, Bostrom A, Nee M, Stamper RL. Clinical comparison of contour and applanation tonometry and their relationship to pachymetry. *Arch Ophthalmol* 2005; 123:1532–1537
34. Tonnu P-A, Ho T, Newson T, El Sheikh A, Sharma K, White E, Bunce C, Garway-Heath D. The influence of central corneal thickness and age on intraocular pressure measured by pneumotonometry, non-contact tonometry, the Tono-Pen XL, and Goldmann applanation tonometry. *Br J Ophthalmol* 2005; 89:851–854
35. Ehlers N, Bramsen T, Sperling S. Applanation tonometry and central corneal thickness. *Acta Ophthalmol (Copenh)*. 1975;53(1):34–43.
36. Incorporating corneal pachymetry into the management of glaucoma Michele lester, Maurizio Mete, Michele Figus, Paolo Frezzotti *Journal of Cataract & Refractive Surgery*. 2009; 35(9), 1623-28
37. Tonnu P-A, Ho T, Newson T, El Sheikh A, Sharma K, White E, Bunce C, Garway-Heath D. The influence of central corneal thickness and age on intraocular pressure measured by pneumotonometry, non-contact tonometry, the Tono-Pen XL, and Goldmann applanation tonometry. *Br J Ophthalmol* 2005; 89:851–854
38. Copt RP, Thomas R, Mermoud A. Central thickness in ocular hypertension, primary open-angle glaucoma, and normal tension glaucoma. *Arch Ophthalmol*. 1999;117:14–16.
39. Emara BY, Tingey DP, Probst LE, et al. Central corneal thickness in low-tension glaucoma. *Can J Ophthalmol*. 1999;34:319–324.
40. Intraocular Pressure, Central Corneal Thickness, and Glaucoma in Chinese Adults: The Liwan Eye Study , 16 June 2011, Dandan Wang, Wenying Huang, Yuetao Li, Yingfeng Zheng, Paul J. Foster, Nathan Congdon, Mingguang He *American Journal of Ophthalmology* September 2011; 152: 454-462
41. P.N. Schacknow and J.R. Samples (eds.), *The Glaucoma Book: A Practical, Evidence-Based Approach to Patient Care*, © Springer 2010, 79-90

# OCULAR RESPONSE ANALYZER

Glaucoma is an optic neuropathy characterized by a progressive loss of retinal ganglion cells. Elevated intraocular pressure (IOP) is a major risk factor for the development and progression of glaucoma. IOP lowering is the mainstay of treatment for glaucoma. Corneal properties, such as corneal curvature and central corneal thickness (CCT) are well recognized parameters that influence IOP measurement using the Goldman applanation tonometry (GAT). However, variations in corneal curvature and CCT do not fully explain the IOP measurement error by GAT. Other factors such as biomechanical properties such as corneal viscoelasticity, may also have an effect on IOP measurement.

## INTRODUCTION

The Ocular Response Analyzer (ORA; Reichert Inc, Depew, NY) is a novel instrument for measuring the intraocular pressure (IOP) of the eye (Fig. 1). It is also the only instrument capable of measuring the biomechanical properties of the cornea. Corneal biomechanical properties influence intraocular pressure measurement, undergo alterations in corneal pathology and following corneal refractive surgery. Corneal Hysteresis (CH), which is the result of viscous damping in the corneal tissue, is a new indicator of corneal biomechanical properties.

## PRINCIPLE

The ORA utilizes a dynamic, bidirectional applanation process for measuring IOP. A rapid air impulse is used to apply force to the cornea. The deformation of the cornea is monitored using an advanced electro-optical system. The precisely metered, collimated air pulse causes the cornea to move inwards causing applanation, similar to conventional noncontact tonometers. However, in the ORA, the air impulse continues to deform the cornea past applanation into slight concavity. Then, the air pump shuts off and, as the pressure decreases, the cornea begins to return to its normal configuration. During this process, it once again passes through an applanated state. The entire process takes only 20 milliseconds, a time sufficiently short to ensure that ocular pulse effects or eye position does not change during the measurement process. These deformation changes are monitored by the electro-optical detection system. Two independent pressure values are derived from the inward and outward applanation events. These two pressure values are not the same. Due to the dynamic nature of the air pulse, viscous damping (energy absorption) in the cornea causes delays in the inward and outward applanation events, resulting in two different pressure values (Fig. 2). The difference between these two pressure values is Corneal Hysteresis (CH). The average of these two applanation events provides a repeatable, Goldmann correlated IOP measurement (IOPg).



Fig. 1: The ocular response analyzer

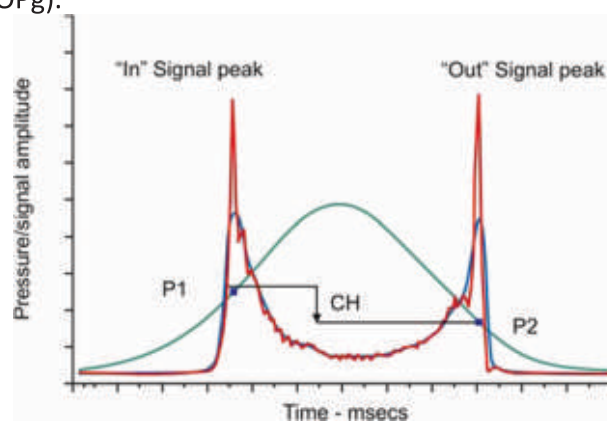


Fig. 2: Ocular response analyzer measurement signals  
Measurement signals—Red: Raw applanation signal,  
Blue: Filtered applanation signal, Green: Air pressure curve

### METHOD OF OPERATION

The patient is seated in front of the machine and asked to fixate on a green light.

The system positions an air tube to a precise position relative to the apex of the cornea. The air pulse then applies pressure to the cornea. Corneal deformation is recorded and measurement signals are obtained. The measurement signals consist of a green symmetric curve, which corresponds to the air pulse pressure, and a red asymmetric curve, which indicates the raw signal corresponding to the applanation of the cornea. The blue curve is a filtered version of the red curve, designed to identify the optimum point of applanation in less than ideal signals. The red curve has 2 principal peaks. The applanation pressure is determined by drawing a line down from the peak of each applanation spike to the intersection of the green pressure curve. These points, P1 and P2 are graphically indicated as blue squares on the green curve. P1 is the pressure at the first applanation event as the cornea moves inward under the increasing force of air pulse (inward applanation). P2 is the pressure corresponding to the second applanation event as the cornea returns to its normal curvature under the decreasing force of the air pulse (outward applanation). P2 is always lower than P1 due to Corneal Hysteresis. The applanation signal curves should have a clearly defined and relatively well-centered high point (peak).

The ORA provides 4 different measurement parameters

**IOPg:** A Goldmann-correlated IOP value.

**CH:** (P1-P2) A measure of viscous damping in the cornea.

**IOPcc** (Corneal-Compensated Intraocular Pressure): An intraocular pressure measurement that is less affected by corneal properties.

**CRF** (Corneal Resistance Factor): An indicator of the overall “resistance” of the cornea.

The ORA also has a built in 20 MHz ultrasound pachymeter that measures central corneal thickness.

Corneal hysteresis is a function of the corneal viscous resistance (damping/energy absorption) properties.<sup>1</sup> Corneal hysteresis is the difference between pressures P1 and P2, a numerical value denoting viscoelastic corneal tissue response to a dynamic deformation. A greater difference generates a higher CH, suggestive of a stiffer cornea. CH is influenced by the rate of force application and is likely linked to the stromal collagen nature and state of hydration.<sup>2</sup> Normal values of CH and CRF measured in a recent study were 10.8 mm Hg  $\pm$  1.5 (SD) and 11.0 mm Hg  $\pm$  1.6 mm Hg respectively. Corneal resistance factor and IOPcc are calculated using a linear combination of P1 and P2.<sup>4</sup> IOPcc measurement is designed to reduce the effect of corneal thickness and properties on the IOP measurement process, wherein the IOP has been adjusted utilizing the information provided by the corneal hysteresis measurement.

### INDICATIONS

The influence of central corneal thickness (CCT) on intraocular pressure (IOP) measurements using Goldmann applanation tonometry (GAT) has been well-recognized.<sup>5,6,7</sup> Intraocular pressure is overestimated in thick corneas or underestimated in thin corneas. However, it is likely that factors other than CCT, including corneal hydration, connective tissue composition, and bioelasticity, contribute to the response of the corneoscleral shell, to the force applied during the measurement of IOP.<sup>8</sup> The ORA provides IOP measurements taking into consideration these biomechanical properties of the cornea (Figs 3 to 5). IOPcc and IOPg have shown good correlation with GAT IOP measurements.<sup>1</sup> GAT IOP measurements are significantly associated with CCT, whereas IOPcc measurements are not associated with any of the variables - CCT, corneal curvature, axial length,

and age.<sup>9,10</sup> The difference between GAT and IOPcc measurements is significantly influenced by corneal thickness.<sup>8</sup> Patients with thicker corneas tend to have higher GAT IOP measurements compared with IOPcc, whereas in patients with thin corneas, GAT IOP measurements tend to be lower than IOPcc. In a study by Congdon et al, lower corneal hysteresis value, but not CCT, was associated with visual field progression.<sup>8</sup> In the study by Touboul et al, CH values were found to be lower in glaucomatous eyes than in normal eyes.<sup>1</sup> CRF was higher than CH values in normal and glaucomatous eyes.<sup>1</sup> True IOP was underestimated by Goldmann applanation tonometry in underdamped corneas and should be an interesting factor in glaucoma management.<sup>1</sup>

Clinical data has shown that the Corneal Hysteresis measurement is useful in identifying corneal pathologies and may be valuable in identifying potential LASIK (laser assisted in situ keratomileusis) candidates who are at risk of developing ectasia. Eyes with keratoconus and Fuchs' dystrophy also have low CH values.<sup>1,11</sup> In a study by Ortiz et al, it was found that higher the keratoconus grade, the lower the corneal hysteresis and corneal resistance factor values.<sup>12</sup> Corneal hysteresis may also be a useful qualification factor for LASIK and related corneal refractive surgery procedures because different subjects with the same corneal thickness may display significantly different corneal mechanical properties.<sup>11</sup> A significant decrease in the IOP and biomechanical properties is found in eyes following LASIK surgery. Both IOPcc and IOPg showed a decrease after LASIK surgery. However, the decrease in IOPcc was much lower than the decrease in IOPg,<sup>12</sup> suggesting that the IOPcc is a more accurate indicator of the true IOP.

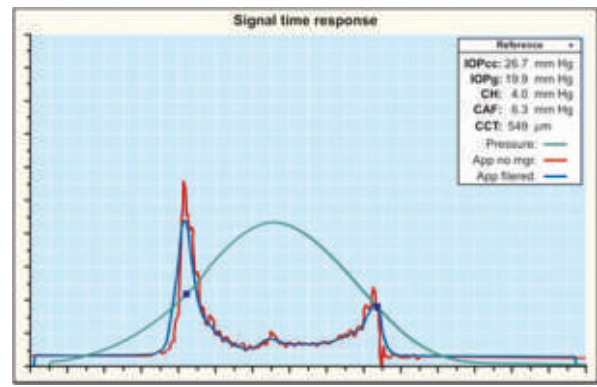


Fig.3 : NTG—IOPcc greater than IOPg, low CH and CRF low amplitude peaks

## SUMMARY

The assessment of corneal biomechanical properties with the ORA is useful in evaluating the influence of corneal properties on IOP measurements. These new, objective methods of IOP measurement appear to be less dependent on corneal rigidity than Goldmann applanation tonometry. The clinical applications of this novel device range from corneal pathology diagnosis, pre-ectasia screening and post LASIK IOP measurement to glaucoma screening, diagnosis and treatment efficacy monitoring. The information obtained using this instrument is invaluable in appropriate, long-term management in these conditions.

## References

1. Touboul D, et al. Correlations between corneal hysteresis, intraocular pressure, and corneal central Pachymetry. J Cataract Refract Surg 2008;34:616-22.
2. Rouse EJ, et al. IOVS 2007; 48: ARVO E-Abstract 1247.
3. Ortiz D, Pinero D, Shabayek MH, et al. Corneal biomechanical properties in normal, post-laser in situ keratomileusis, and keratoconic eyes. J Cataract and Refract Surg 2007;33:1371-75.
4. Luce DA. IOVS 2006;47:ARVO E-Abstract 2266.
5. Whitacre MM, Stein RA, Hassanein K. The effect of corneal thickness on applanation tonometry. Am J Ophthalmol 1993;115:59-596.
6. Liu J, Roberts CJ. Influence of corneal biomechanical properties on intraocular pressure measurement: quantitative analysis. J Cataract Refract Surg 2005;31:146-55.
7. Whitacre MM, Stein R. Sources of error with use of Goldmann type tonometers. Surv Ophthalmol 1993;38:1-30.
8. Congdon NG, et al. Central Corneal Thickness and Corneal Hysteresis Associated With Glaucoma Damage. Am J Ophthalmol 2006;141:868-75.
9. Medeiros FA, Weinreb RN. Evaluation of the Influence of Corneal Biomechanical Properties on Intraocular Pressure Measurements Using the Ocular Response Analyzer. J Glaucoma 2006;15:364-70
10. Pepose JS, et al. How Should We Measure IOP Following LASIK? Cataract and Refractive Surgery Today 2005;2-4.
11. Luce DA. Determining in vivo biomechanical properties of the cornea with an ocular response analyzer. J Cataract Refract Surg 2005;31:156-62.
12. Ortiz D, et al. Corneal biomechanical properties in normal, postlaser in situ keratomileusis, and keratoconic eyes. J Cataract Refract Surg 2007;33:1371-75.



# EVALUATION OF THE OPTIC NERVE HEAD

A change in the appearance of the optic nerve can be the first finding in a glaucoma patient. Thus, stereoscopic view of the optic disc to recognize characteristic features of glaucomatous optic neuropathy is of extreme importance in glaucoma diagnosis and management. A variety of contact and non-contact lenses can be used for stereoscopic viewing of the fundus with the help of a slit lamp. Non contact lenses (like + 60D, +78D, + 90D) are more convenient than contact lenses and are widely used.

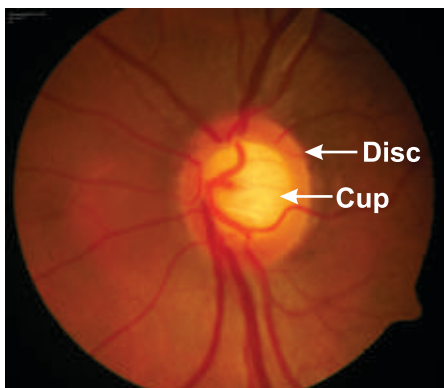
A systematic approach to disc assessment prevents many a glaucoma cases from being missed. Paying attention to the **5Rs** during optic disc examination is a concept created by Robert N Weinreb MD, Felipe Medeiros MD and Remo Susanna Jr MD and can be utilized to standardize the examination and documentation of the optic nerve and nerve fibre layer.

## THE FIRST R : Optic disc size and shape (Scleral Ring)

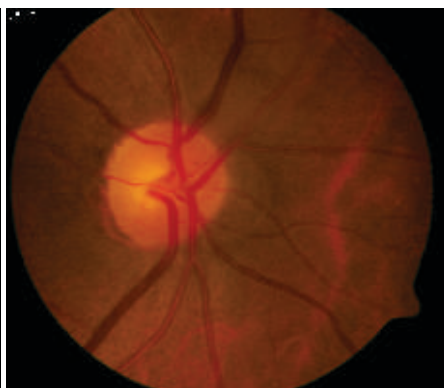
The inner edge of the Scleral Ring is observed to identify limits and size of the optic disc. Disc size is variable with average/medium sized discs having vertical diameter of 1.4 – 2mm, small disc  $\leq 1.3$  mm and large disc  $> 2$  mm.

Disc size can be estimated during slit lamp examination by adjusting the height of the slit beam to correspond with the margins of the disc and noting the reading from the graticule. The appropriate magnification factor must be multiplied to get the correct measurement depending on the lens used (60D x1, 78D x 1.1, 90D x 1.3) during examination.

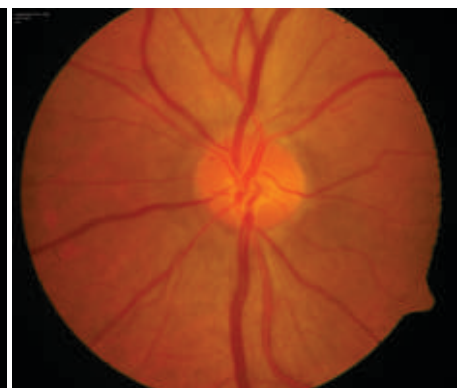
Along with the disc size, the vertical and horizontal **cup disc diameter ratios (CDR)** need to be documented as this is necessary for quantification of glaucomatous optic neuropathy. Armaly back in '70s introduced the idea of CDR, which is expressing the proportion of the disc occupied by the cup. Any vessel displacement, any sloping, depth of the cup also needs to be documented. However, the cup-disc ratio has its limitations as it is subject to wide variability. A high CDR can be normal in a large disc where as a low CDR may be glaucomatous if the disc is small. Margin of the cup is delineated by the bending of the disc vessels. In general, CDR of .7 in an average sized or large disc should be viewed with suspicion. If there is asymmetry or CDR differs by more than 0.2 in both eyes of a patient, the possibility of glaucomatous damage should be considered, if other causes of asymmetry have been ruled out.



Large disc large cup



Medium disc 0.3 CDR

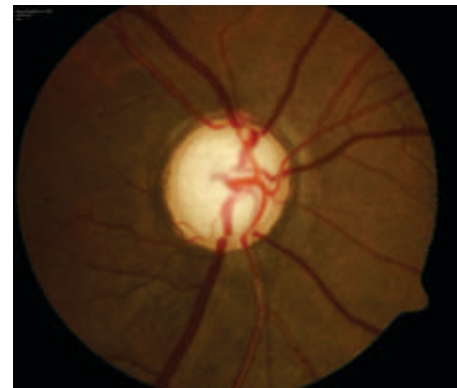

Small disc small cup

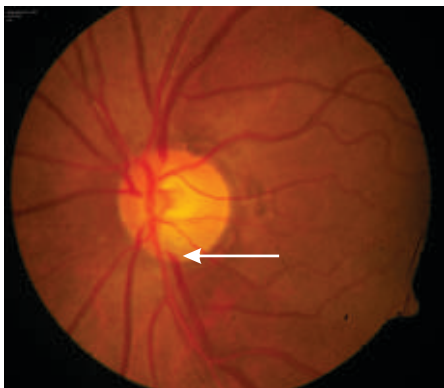## THE SECOND R : Neuro Retinal Rim Evaluation

The area of the optic disc occupied by axons is called the neuroretinal rim (NRR). The thickness, colour and contour of neural rim should be compared in each of the four quadrants. Glaucomatous damage may be diffuse, focal or a combination. Diffuse damage results in symmetrical enlargement of the cup with generalized rim thinning while focal damage leads to localized loss of NRR. Focal loss of NRR is called a **notch** which is highly suggestive of glaucoma and produces a corresponding functional field defect. Normally the inferior (I) rim is thickest, followed by superior (S), nasal (N) and then temporal (T) (**ISNT rule**). An inferior or superior rim equal to or thinner than temporal rim is highly suspect. The thinning may or may not extend to the edge of the disc. Nowadays, **rim-to-disc ratio** is considered to be more important than CDR. A rim-to-disc ratio of less than 0.1:1 in any area should be considered pathological.

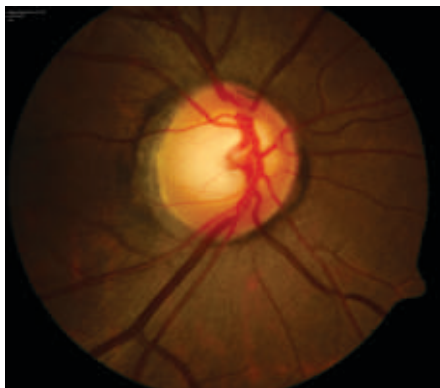The normal pink colour of NRR may be pale (yellow, gray or white) due to atrophic tissue in glaucoma, some retinal pathologies, AION, chiasmal compression etc. If pallor is more than area of cupping, then causes other than glaucoma must be kept in mind.



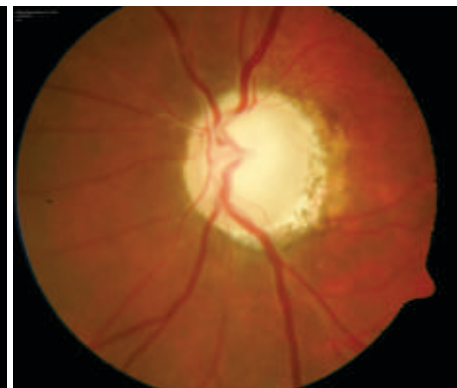Generalised NRR thinning



Localised NRR thinning (inferior notch)



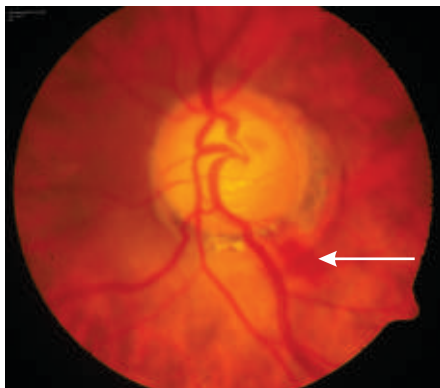Disc pallor = cup area



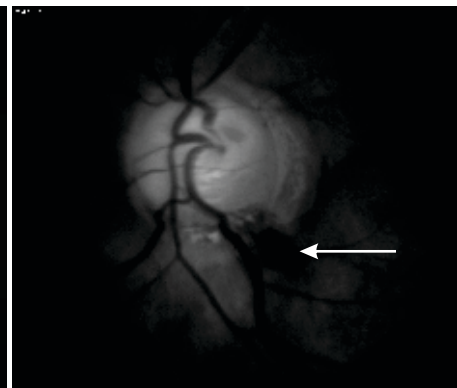
Disc pallor > cup area

## THE THIRD R : Retinal and optic disc hemorrhages

Optic disc hemorrhages (Drance hemorrhage) are usually splinter or flame shaped on the disc surface usually in superotemporal or inferotemporal rim. More commonly seen in normal tension glaucoma, these hemorrhages are transient and last for usually about 2 – 4 months. Corresponding visual field defects may appear weeks to years later. Patients with disc hemorrhages are at a higher risk of developing glaucoma (ref OHTS). Disc hemorrhages may occur rarely in normal eyes. Other causes such as PVD, trauma, hypertension and use of anti coagulants like aspirin should be kept in mind.



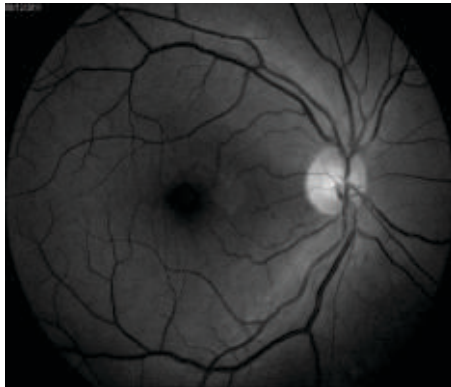
Optic disc hemorrhage



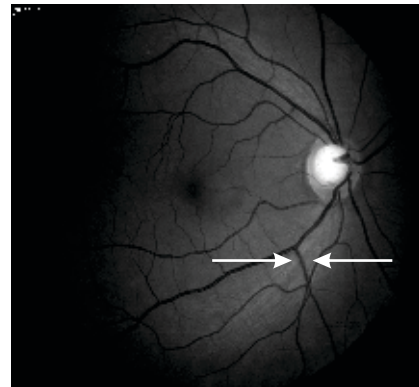
Disc hemorrhage in red free light

### THE FOURTH R : Retinal Nerve Fibre Layer Defect

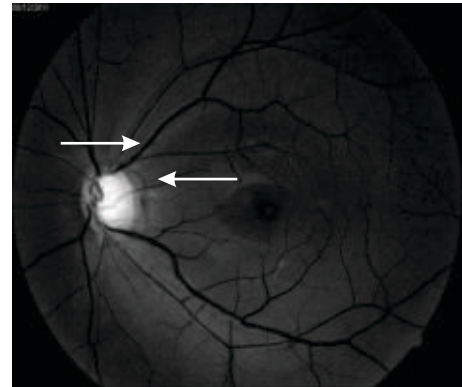
The **Retinal Nerve Fibre Layer (RNFL)** corresponds to the nerve fibres passing from the photoreceptors over the retina as they course towards the optic disc. RNFL examination is best performed using red-free green light through a dilated pupil. In affected areas, the normal silvery striations are lost and fundus appears darker and deeper red in these areas. Slit defects may be physiological. Wedge shaped defects extending upto the disc margin are typical of glaucoma. In later stages of glaucoma, diffuse atrophy of RNFL is seen.



Healthy RNFL



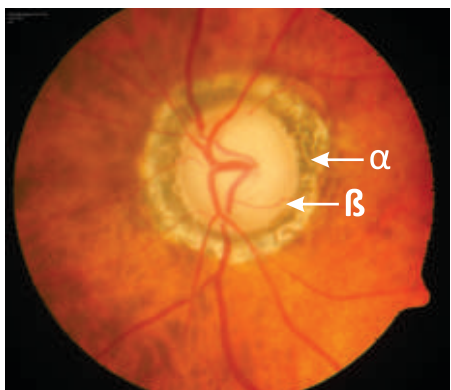Slit defect in RNFL



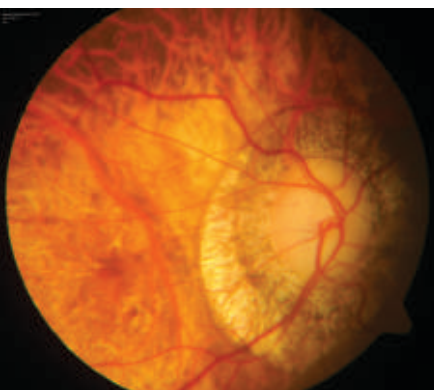
Wedge defect in RNFL

### THE FIFTH R : Region of Peripapillary Atrophy (PPA)

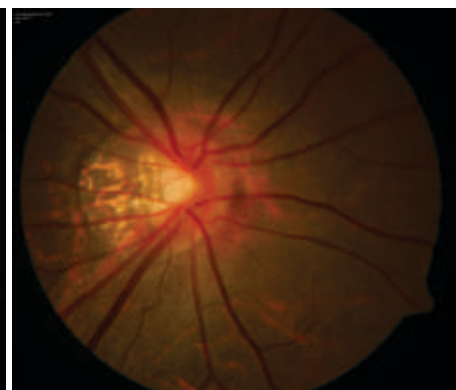
Evaluation of PPA aids in glaucoma assessment. Two distinct zones of atrophy- alpha and beta surround the optic disc. Peripheral alpha zone is an irregular hypo or hyper pigmented zone associated with chorioretinal thinning. This zone is found in many normal eyes. The inner beta zone represents loss of retinal pigment epithelium and choriocapillaries leaving intact choroidal vasculature. Beta zone atrophy is seen more in glaucomatous eyes and increases with progress of disease. PPA may be focal or circumferential. Alpha and beta zones have to be differentiated from crescents in myopic eyes and in eyes with tilted discs.



Glaucomatous disc with PPA



Myopic disc with PPA



Tilted disc with PPA

### OTHERS

**Acquired pit of the optic nerve (APON)** – This is usually associated with localized excavation of the NRR. It is strongly associated with glaucoma and usually present in supero and inferotemporal regions of the disc.

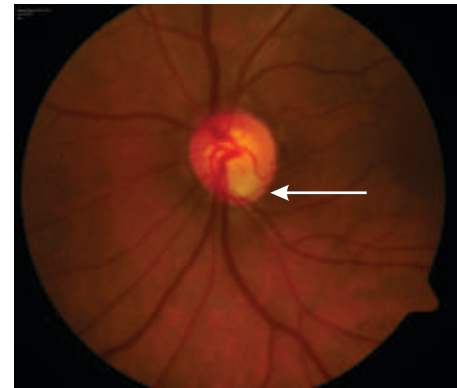


Bayoneting of blood vessels is kinking or bending of blood vessels when they pass over the edge of the cup. It is a sign of erosion or loss of NRR.

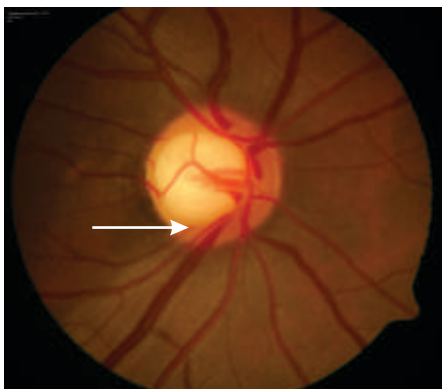Baring of blood vessels are seen when arc-shaped vessels are left bare or isolated from the margins of the cup due to loss of NRR.

Bridging (Overpass) is when disc vessels hang over an area of lost neural tissue.

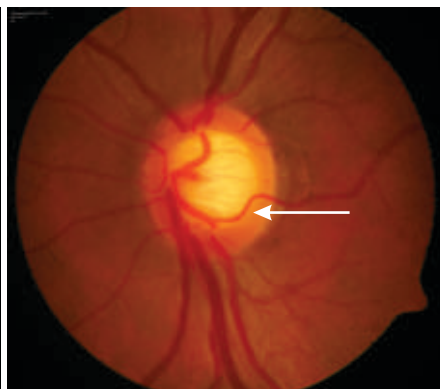### THE DISC DAMAGE LIKELIHOOD SCALE



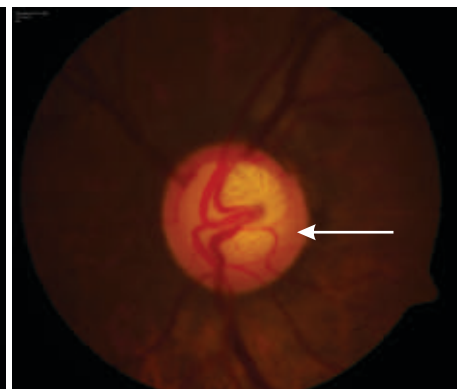Acquired Pit



Bayoneting of vessels



Baring of vessels



Overpass vessel

An enlarged cup disc ratio is undoubtedly linked with glaucomatous loss but the disadvantages of the CDR system (Armaly 1967) for diagnosing and quantifying glaucoma are the variation in cup sizes in the population and more importantly, the fact that all discs do not grow concentrically and eccentric cups may display localized notching. The other important aspect is the variation in disc size and the fact that larger cups have more nerve fibers than smaller cups. This in turn mean that a lower cup disc ratio for a smaller cup is more significant than the same ratio for a larger cup, as it represents more neuropathy. There may be significant intra and inter observer error in this method.

To overcome these problems, the Disc Damage Likelihood Scale (D.D.L.S.) was brought forth by Dr George L Spaeth et al in 2002 to incorporate the effect of disc size and focal rim width into a clinical grading scale. It is highly reproducible and does correlate strongly with the degree of field loss. This system is based on the narrowest neuroretinal rim width in any position and if no rim is present, the circumferential extent of absence of the rim. The rim is defined as the width between the outer edge of the disc and inner edge of the rim, this inner edge being the position where the surface of the disc starts to bend posteriorly towards the lamina. There are 10 D.D.L.S. stages. The DDLS relies on the optic nerve as a direct indicator of disease. As the scale divides glaucomatous progression into 10 stages, it can monitor disease progression better.

Any disc graded stage 5 or higher is unhealthy. It will almost always be pathologic, although it may not be glaucomatous. Damage from glaucoma will usually be infero or superotemporal. DDLS scores of 1 through 3 are rarely associated with glaucomatous visual field loss. Some individuals are born with DDLS 3 optic discs, whereas others begin with DDLS 1 discs. For this reason, noting that a person has a DDLS 3 optic disc indicates that it is reasonably healthy and that there is no visual field loss. This score is not proof that the disc's health has
































not worsened, however, because it could have been a stage 1 or 2 in the past.

## Categorization

The DDLS allows you to quantify the amount of damage that the optic nerve has sustained. Visual field loss usually will not occur before stage 5. The differentiation between very early and no damage is important, because a neuroretinal rim that has already narrowed is likely to become narrower still, whereas an undamaged rim is far more likely to remain stable. One may choose to defer treatment and observe closely patients with optic nerves of stages 0 through 5, because the consequences of treatment may outweigh those of nontreatment. Unless glaucomatous progression has stabilized (eg, in cases of inactive glaucoma secondary to trauma or corticosteroids), a DDLS score of 6 through 10 strongly supports aggressive treatment.

## Monitoring

The stability of a patient's glaucoma is often best determined by evaluating the optic disc. The DDLS scores maybe recorded on the patients' charts every time the fundus is examined, meaning at every visit when assessment is being made whether their glaucoma is stable, improving, or deteriorating.

DDLS Stage	Narrowest width of rim (rim/disc ratio)			DDLS Stage	Examples		
	For Small Disc <1.50 mm	For Average Size Disc 1.50-2.00 mm	For Large Disc >2.00 mm		1.25 mm optic nerve	1.75 mm optic nerve	2.25 mm optic nerve
1	.5 or more	.4 or more	.3 or more	0a			
2	.4 to .49	.3 to .39	.2 to .29	0b			
3	.3 to .39	.2 to .29	.1 to .19	1			
4	.2 to .29	.1 to .19	less than .1	2			
5	.1 to .19	less than .1	0 for less than 45°	3			
6	less than .1	0 for less than 45°	0 for 46° to 90°	4			
7	0 for less than 45°	0 for 46° to 90°	0 for 91° to 180°	5			
8	0 for 46° to 90°	0 for 91° to 180°	0 for 181° to 270°	6			
9	0 for 91° to 180°	0 for 181° to 270°	0 for more than 270°	7a			
10	0 for more than 180°	0 for more than 270°		7b			

# STANDARD AUTOMATED PERIMETRY

Automated static perimetry is the most important tool for diagnosis of glaucoma.<sup>1</sup> It measures the visual function outside the fovea within central 30 degrees of visual field as most of the visual field defects in glaucoma occur within these limits. A reproducible field defect in this area is taken as concrete evidence in favor of glaucomatous optic neuropathy. Currently, this is the most indispensable tool for diagnosis of glaucoma and its progression.<sup>2</sup> Optic disc imaging and nerve fibre layer measurements are useful tools but they have not yet replaced perimetry in diagnosing and managing glaucoma.<sup>3</sup>

## Visual fields in glaucoma

Glaucomatous visual field loss commonly occurs in the arcuate area in the superior and inferior hemi fields.<sup>4</sup> These areas arch around the fovea, starting from optic disc and extending nasally to end at the horizontal raphe. A relative decrease in retinal sensitivity (relative scotoma) in this area is usually the first evidence of glaucoma. These scotomas tend to occur nasally and there is significant asymmetry between the superior and inferior hemi-fields.

Localized field defects are hallmark of glaucoma but frequently they are associated with overall reduction in sensitivity. A pure generalized reduction of sensitivity is not typical of glaucomatous visual loss and is more likely to be due to media opacities.

## Visual field testing for glaucoma

Humphreys visual field analyser is one of the popular perimeters in clinical use, therefore, following discussion mostly refers to this perimeter. Basic concepts are applicable to other perimeters (e.g. Octopus) as well and can be used for interpreting visual fields.

Standard Automated Perimetry (SAP) is white on white perimetry performed using predefined threshold measuring algorithms usually a 30-2 test.<sup>5</sup> Usually one of the following tests is used; 30-2 full threshold, 30-2/24-2 SITA Standard or 30-2/24-2 SITA Fast. SITA strategy takes less time than full threshold without losing its diagnostic ability and is generally preferred. 30-2 tests 76 points in the central 30 degrees in a grid like manner. The test locations are 6 degrees apart from each other. 24-2 pattern is very similar to 30-2 except that outermost row of test locations is eliminated. As a result it tests only 54 points in the central 24 degrees.

SITA Standard is a thresholding algorithm that is quite quick and accurate and has largely replaced the full threshold program in clinical use.<sup>6</sup> It takes about 4 – 8 minutes per eye depending on the test pattern and the status of the eye. Selection of test depends on the status of the eye as well as on patients ability to perform the test. 24-2 or 30-2 test pattern using SITA Standard is the most commonly prescribed test for glaucoma. In advanced cases where 24-2 or 30-2 pattern does not give enough information it is advisable to use a 10-2 pattern.

Since glaucoma is a chronic disease and needs follow up with visual fields, it is best to stick to the same test pattern and thresholding algorithm for subsequent tests. It helps make more meaningful comparisons to detect progression. From follow up point of view establishing a good baseline is very important. Due to test retest variability visual field should be repeated 2-3 times in the beginning at shorter intervals to get at least two similar fields. Subsequently any change found on follow up fields must be confirmed on repeat testing.

### Interpreting visual field charts

It is best to look at the visual field print out in a systematic manner for proper interpretation. Humphrey's visual field print out has following components and each must be considered for proper interpretation (Fig. 1):

#### Demographic data:

Patients name, identification number, date of birth are printed on top along with date and time of testing, eye tested.

#### Test conditions:

Visual acuity and size of the pupil, refractive correction used, Stimulus size and color, back ground illumination, test pattern and thresholding strategy use are also mentioned in the upper part of the print out. It is desirable to keep the test conditions comparable from one examination to another for meaningful individual and group comparisons.

#### Reliability Indices:

Reliability is evaluated by monitoring fixation losses, false positive and false negative responses.<sup>7</sup> Fixation losses are monitored by projecting stimulus in the blind spot area and by using a gaze tracker in newer machines. Fixation losses up to 15% are acceptable for a reliable test. False Positive errors refer to number of times patient responds when there is no stimulus. False Negative errors refer to the number of times patient fails to respond when a supra-threshold stimulus is presented. A false positive rate of 20% or more is considered abnormal.

#### Gray scale printout:

This is a graphical representation of the decibel values obtained. This gives an immediate and easily comprehensible status of the visual fields. It is useful while discussing the visual field loss with the patients as they can see the dark areas in the field and can relate them to loss of function. It is useful when visual loss is moderate to severe. Early field loss may be missed on gray scales.

#### Numerical Scale Printout (Raw data):

They show the actual measured threshold values and difficult to interpret as such. All other analyses and printouts are based on these values. Probability plots are much easier to interpret but occasionally these values may provide a further insight in to the test results.

#### Total Deviation Probability Plots:

Total deviation plots are helpful as they highlight the areas that fall outside the normal range. These values are corrected for age. Negative value indicate a value lower than the age corrected median sensitivity for that location. A probability value is calculated for each test location and all test locations that are significantly depressed are marked with probability symbols. This is a quick and easy way of knowing which test locations are depressed and to what extent. A test location showing a  $p < 2\%$  means that fewer than 2% of normal people are likely to have such low sensitivity at that location. Total deviation probability plots can not distinguish between a localized field defect or a more generalized field defect due to media opacity.

#### Pattern Deviation Probability Plots:

The pattern deviation plots highlight the localized field defects, which are typical of glaucoma. The areas that

deviate significantly from normal are first corrected for overall decrease in retinal sensitivity. It reduces the effect of generalized depression due to media opacities such as cataract. Pattern deviation plots are most useful for the diagnosis and monitoring of glaucoma. Like total deviation plots, pattern deviation plots also use symbols to indicate the level of significance of the observed change.

### Glaucoma Hemifield Test (GHT):

GHT is based on the fact that field loss in glaucoma is not symmetrical in superior and inferior hemi-fields. Sensitivity values in five predetermined zones in the superior hemifield are compared with the corresponding values in the lower hemifield.<sup>8</sup> This test has a high sensitivity and specificity for detecting glaucoma. There are six possible outcomes of this test:

1. Within normal limits. Means the test is normal and overall sensitivity is within 99.5% range of normal.
2. Outside normal limits. There is significant difference between the sensitivities in the superior and inferior hemifields and the difference is greater than expected in 99% of normal population.
3. Borderline. Means that threshold differences are greater than 95% but less than 99% of the expected in the normal population.
4. General reduction in sensitivity. When overall sensitivity is less than 99.5% range of normal but there is no difference between the superior and inferior hemifields.
5. Abnormally high sensitivity. When overall sensitivity is higher than the expected in 99.5% of normal population. Usually associated with high false positive responses and is seen in trigger happy patients.
6. Borderline with general reduction in sensitivity. When there is generalized reduction in sensitivity but the superior and inferior hemifields differ significantly.

### Global Indices:

Mean Deviation (MD) and Pattern Standard Deviation (PSD) and Visual Field Index (VFI) are useful in knowing the overall status of the fields. MD is a measure of average difference between the measured threshold value at each location and expected value in age matched normal subject. PSD is the standard deviation of the mean difference between the measured threshold value at each location and expected value in age matched normal subject. If MD or PSD is outside normal range, a p value appears next to indicating the level of significance.

### Diagnosis of Glaucoma:

Various perimetric definitions of glaucoma and its progression have been used in different studies. Anderson's criteria are commonly used to define abnormality in visual fields.<sup>9</sup> As per this criteria, presence of a cluster of three or more nonedge points on the pattern deviation probability plot deviating at  $p < 5\%$ , with one of these points deviating at  $p < 1\%$ ; pattern standard deviation (PSD) having a value ( $p < 5\%$ ); or glaucoma hemifield test (GHT) outside normal limits, is considered abnormal. For the diagnosis of glaucoma two of three criteria should be fulfilled.

### Diagnosis of Severity of Glaucoma:

Visual fields are often used to categorize the severity of the disease. Hoddop-Parish-Anderson's classification is frequently used for this purpose.<sup>10</sup> According to this classification glaucoma is categorized as early loss, moderate or severe loss as follows:



### Early loss:

Mean deviation of more than -6dB and on pattern standard deviation plot at least 3 arcuate depressed points and 7 to 17 points depressed at or below 5% and 10 or fewer points depressed at or below 1% and no points in the central 5 degrees at 0dB and no hemifield pairs in the central 5 degrees at or below 15dB.

### Moderate loss:

Mean deviation between -12dB and -6dB or on pattern standard deviation plot: 18 -36 points depressed at or below 5% or 10-19 points depressed at or below 1% and no points in the central 5degrees at 0dB and no hemifield pairs in central 5 degrees at or below 15dB.

### Severe loss:

Mean deviation worse than -12dB or on pattern standard deviation plot: 37 or more points depressed at or below 5% or 20 points depressed at or below 1% or one or more points in the central 5 degrees at 0dB or hemifield point pairs in the central 5 degrees at or below 15dB.

### Detecting Progression on Visual Fields

Detection of glaucoma progression on visual fields is complex and there is no standard way of doing it.<sup>11</sup> Long term variability or fluctuations are common and tend to be more marked in patients with glaucoma. This makes it difficult to decide whether the observed field loss is due to glaucoma or part of normal variability. This is compounded by the fact that there is no 'Gold Standard' definition of progression.<sup>12</sup> Multiple visual field examinations are needed to diagnose progression. It is said that there should be at least four repeatable visual fields before progression can be diagnosed. Inspection of individual printouts can be done to look for progression but it is not reliable. Humphrey Software provides tools like overview printouts, Glaucoma change analysis printout, Glaucoma change probability analysis and Guided progression analysis for detecting progression. The overview printouts are a convenient way of looking at data from multiple tests but do not perform any statistical analysis. Other tests use built in statistical tools to determine the signification of changes observed.

Visual field progression in glaucoma may occur as development of a new defect, deepening or enlargement of an already existing defect or a diffuse loss of sensitivity. Most frequently glaucomatous progression is seen as deepening of existing scotoma.<sup>13</sup>

There are two main approaches to analyze visual fields for progression. Trend based analysis and event based analysis. In event based analysis current examination is compared with a previous base line examination. If the current examination is significantly worse, progression is indicated. In trend based analysis all examinations done in a specified period of time are analyzed. The values are plotted over time and regression line is drawn. The slope of the regression line gives the significance of the change and also the rate of progression.

Humphrey's perimeter has built in tools such as Glaucoma Change Probability (GCP) and Guided Progression Analysis (GPA, Fig. 2) to diagnose progression. GCP compares individual points on a follow up examination with the base line examination. Progression is indicated if two or more adjacent points within or adjacent to a scotoma show significant deterioration. GCP is based on total deviation plot and hence can be affected by media opacities.

GPA is similar to GCP except that it is based on pattern deviation plot. Therefore, it is less likely to be affected by media opacities such as cataract. If significant deterioration present in 3 points is repeatable over 2 consecutive

follow-ups, it is labeled as possible progression. If the same change is repeatable over 3 consecutive follow-ups, it is leveled as likely progression.

### VFI and VFI progression plot

Visual Field Index (VFI) is a newly developed tool which is calculated as the percentage of normal visual field. Therefore, a VFI of 100% represents a normal field whereas a VFI of 0% indicates perimetric blindness. On GPA print out VFI for each examination is shown as a percent value and is also plotted against age for trend analysis. VFI is based both on pattern deviation and total deviation plots and is supposed to perform better.<sup>14</sup> VFI progression plot also gives estimate of visual loss expected in next 5 years based on the current rate of progression. This is useful in estimating the number of years before patient becomes perimetrically blind so that appropriate changes can be made to his therapy.

### How frequently the fields should be repeated:

Glaucoma is a slowly progressive disease and needs long term follow-up. Rate of progression is different for different individuals; hence, there is no set formula on how frequently the fields should be done. Higher frequency of field examinations favors detection of progression.<sup>15</sup> Frequency of examinations should be more in the beginning to identify fast progressors; six visual field examinations have been suggested in the first two years. Later on frequency can be reduced to once or twice a year as long as no change is detected. If change is detected, it should be confirmed as soon as possible. Patients with severe loss, pseudoexfoliative disease, higher intraocular pressure, thin cornea need more frequent fields.

### Limitations of Perimetry

Perimetry is a subjective test and its result can be influenced by a number of environmental and patient related factors. It is difficult to perform in patients with poor vision, very elderly patients, patients with certain physical or psychological disabilities and even in otherwise healthy patients there is some learning curve. Perimetry only tells about the functional defect in the field of vision, which should be correlated with optic disc and retinal nerve fiber layer changes to make the diagnosis of glaucoma.

### Key Points:

- Visual field examination is essential for diagnosis and management of glaucoma and must be done in all patients of glaucoma or suspected glaucoma.
- It is important to have a good baseline visual field right in the beginning. To have good base line field the test may have to be repeated 2-3 times or more at short intervals.
- Test conditions should not vary significantly from one examination to other. This will help get reproducible fields and meaningful comparisons during follow-up.
- Same default test should be used in all patients unless there is a specific reason to change. This makes future comparisons easy. In most cases 30-2 or 24-2 test using SITA standard (Humphrey Perimeter) is adequate.
- Fields should be reliable. Unreliable fields should be ignored and test repeated.
- Field charts should be read in a systematic manner giving due attention to all components of the printout.
- Diagnosing glaucoma progression on visual field is complex. There is no standard test to diagnose progression or a universally accepted definition of progression.

- Built in software tools are useful and should be used to diagnose glaucoma and progression on visual fields.
- Visual field must be repeated periodically. The frequency of test depends on severity and stability of glaucoma.
- There are several limitations of visual field testing and they should be kept in mind while ordering and interpreting visual fields.
- For diagnosis of glaucoma visual field changes must correlate with the clinical findings.

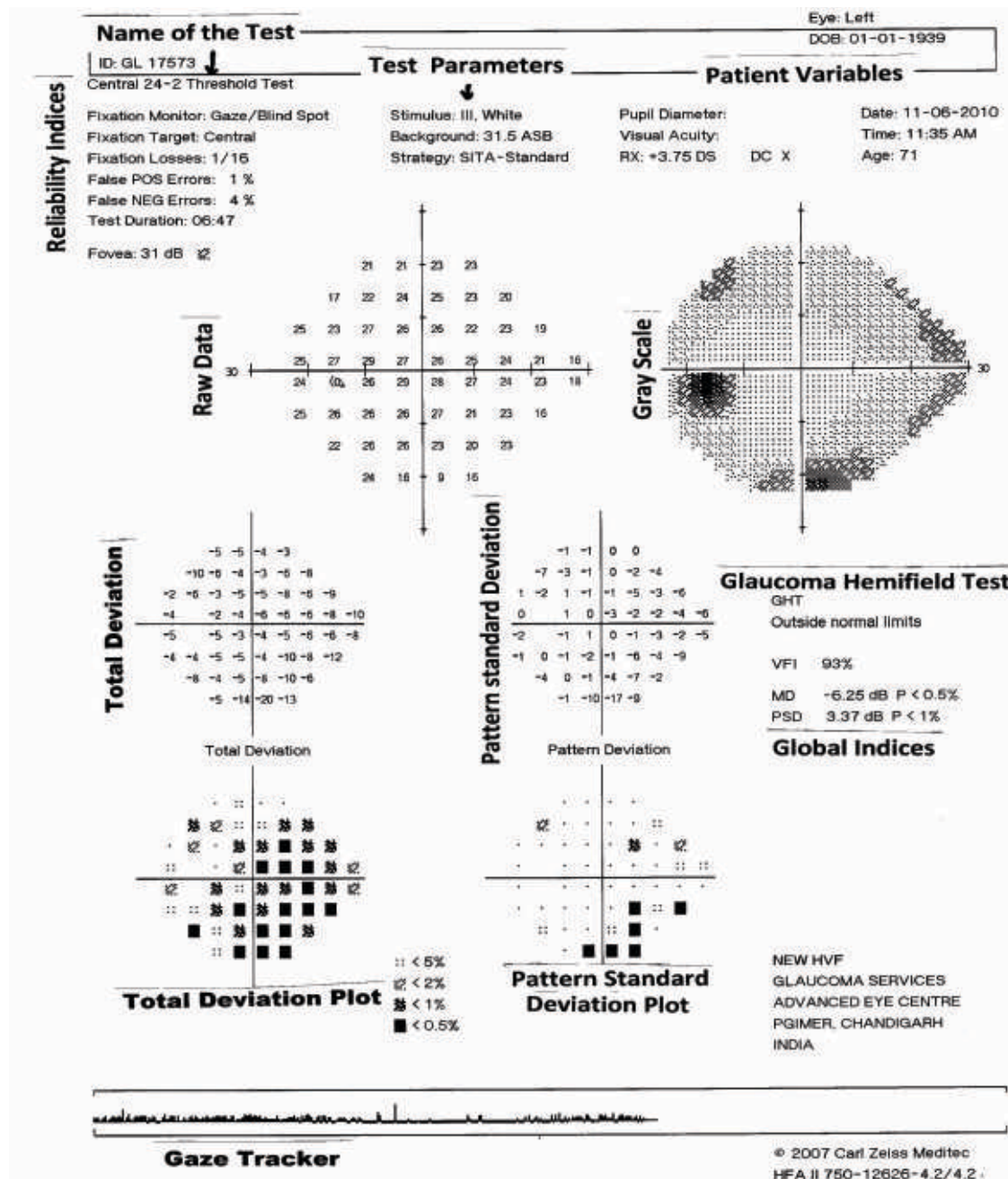


Fig 1. Single field analysis printout (Humphrey's) Showing various components for systematic evaluation.



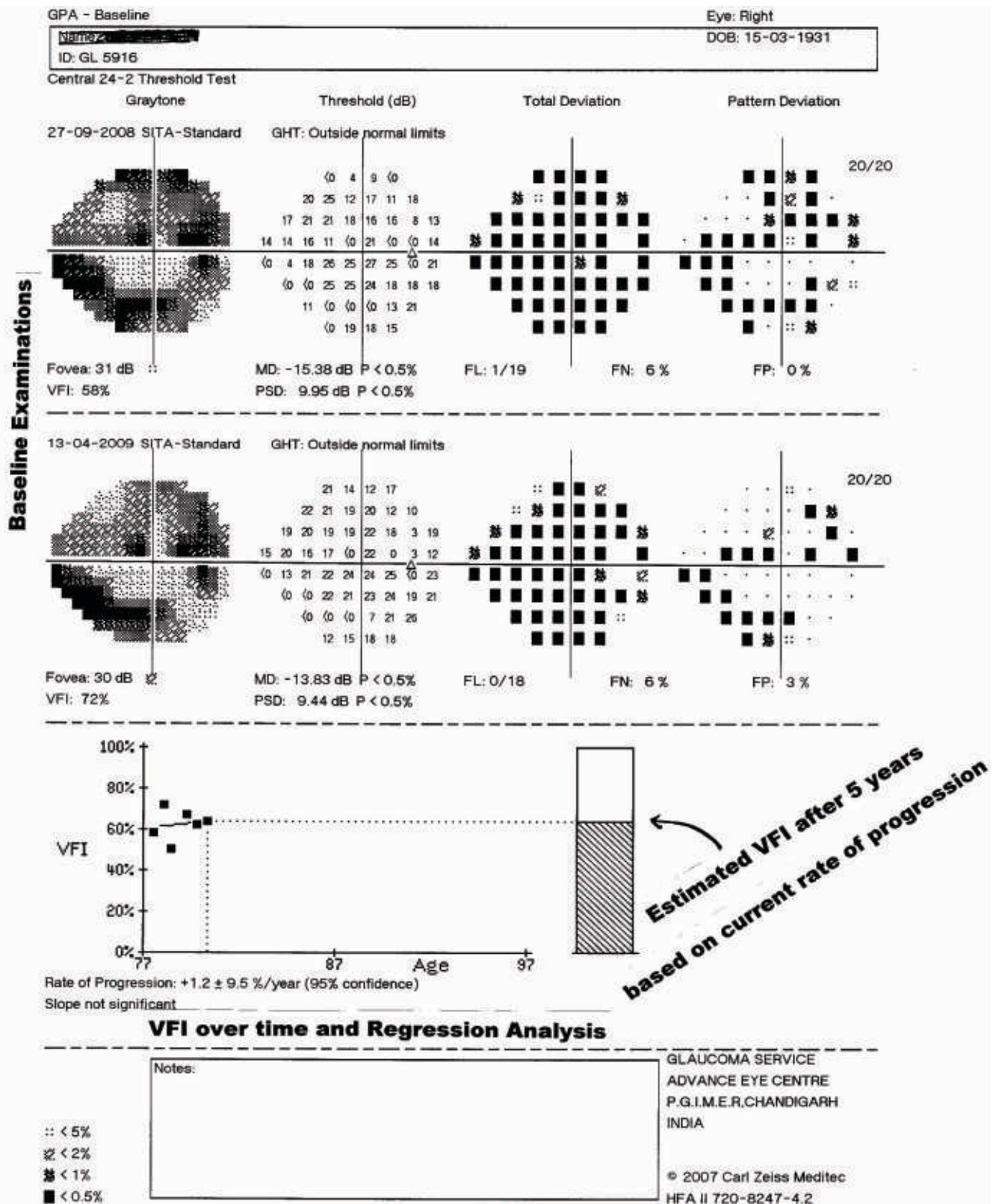


Fig 2a. GPA printout showing 2 baseline fields in the upper part and VFI plotted against age in the lower part to get regression slope and rate of progression. There is no progression over a period of 3 years.



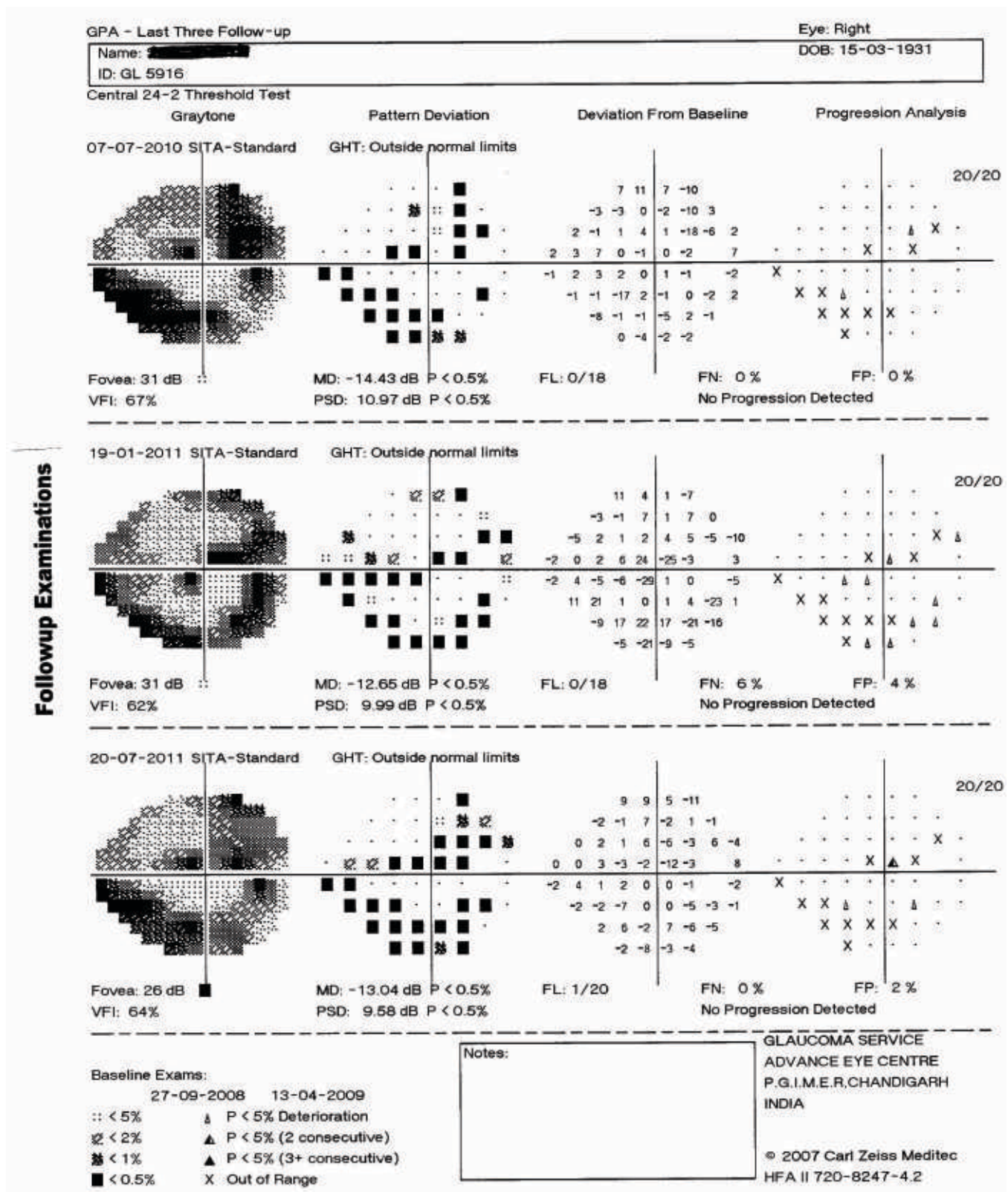


Fig 2b. GPA printout showing event based analysis follow-up examinations. Each follow-up examination is compared point wise with the baseline examination. Significant changes are marked in the right most column. Open triangle indicates significant change detected for the first time, half filled triangle means change detected on two consecutive follow-ups and completely filled triangle means significant change detected on 3 or more consecutive follow-ups.

## References

1. Americal Academy of Ophthalmology. Ophthalmic procedures assessment automated perimetry. *Ophthalmology*. 1996;103:1144-51.
2. Miglior S, Brigatti L, Lonati C, et al. Correlation between progression of optic disc and visual field changes in glaucoma. *Curr Eye Res*. 1966; 15:145-9.
3. Miglior S, Casula M, Guareschi M. Clinical ability of Heidelberg retinal tomograph examination to detect glaucomatous visual field defects. *Ophthalmology*. 2001;108:1621-7.
4. Budenz DL. Atlas of visual fields. Philadelphia: Lippincott-Raven; 1997:143-94.
5. Anderson DR, Patella VM. Automated static perimetry. 2<sup>nd</sup> ed. St. Louis: Mosby; 1999:191-245.
6. Bengtsson B, Heijl A, Olsson J. Evaluation of a new perimetric threshold strategy, SITA, in patients with manifest and suspect glaucoma. *Acta Ophthalmologica Scand*. 1998; 76:268-72.
7. Vingrys AJ, Demirel S. False response monitoring during automated perimetry. *Optum Vis Sci*. 1998;75:513-17.
8. Asman P, Heijl A. Glaucoma hemifield test automated visual field evaluation. *Arch Ophthalmology*. 1992;110:812-19.
9. Anderson DR, Patella VM. A Automated static perimetry, Mosby, St. Louis (1992), pp. 10–35
10. Hoddop E, Parrish RK II, Anderson DR. Clinical decisions in glaucoma. St Louis MO: CV Mosby (1993), pp 52-61.
11. Katz J, Congdon N, Freidman DS. Methodological variations in estimating apparent progressive visual field loss in clinical trials of glaucoma treatment. *Arch Ophthalmol*. 1999; 117:1137-42.
12. Smith SD, Katz J, Quigley J. Analysis of progressive change in automated visual fields in glaucoma. *Invest Ophthalmol Vis Sci*. 1996;37:1419-28.
13. Boden C, et al. Pattern of visual field progression identified by three progression criteria. *Am J Ophthalmol*. 2004;138:1029-36.
14. Bengtsson B, Heijl A. A visual field index for calculation of glaucoma rate of progression. *Am J Ophthalmol*. 2008;145:343-53.
15. Chauhan BC, et al. Practical recommendations for measuring rates of visual field change in glaucoma. *Dr. J Ophthalmol*. 2008;92:569-73.

# FREQUENCY DOUBLING PERIMETRY AND SHORT WAVELENGTH AUTOMATED PERIMETRY

## INTRODUCTION:

Retinal ganglion cells (RGC) are primarily responsible for the organization and processing of visual functions. The predominant P cells (80%) have thinner axons, slow conduction velocity and are responsible for high spatial (fine detail) and low temporal frequency (slow) changes. The K cells (5%) are blue sensitive, whereas M cells (15%) have thicker axons and faster conduction velocity and are primarily responsible for low spatial (large object/coarse detail) and high temporal frequency (rapid changes).<sup>1,2</sup>

Thus either a preferential damage to these discrete RGC or due to the minimal redundancy in this system, there may be an ability to reveal glaucomatous losses early. This is the underlying mechanism of action of FDP and SWAP.

## FREQUENCY DOUBLING PERIMETRY

### Frequency Doubling Illusion:

First described by Kelly<sup>3</sup>, frequency doubling illusion causes doubling of a coarse contrast grating which is rapidly counterphase flickered (Figure 1). Two factors influence whether the illusion is seen—first the spatial frequency of grating and secondly the temporal frequency at which its contrast is modulated. Typically these gratings have low spatial frequency (<1 cycles/degree) and high temporal flicker (>15 Hz). In other words, the number of black and white bands of a vertical grating appears double when rapidly alternated. Maddess and Henry<sup>4</sup> showed a good sensitivity and specificity in discriminating glaucomatous from normal subjects. The illusion is believed to be due to the non linearity in visual system's response to contrast and is thought to be mediated by M cells (especially My subset; which constitute 3-4% of total RGC's and 25% of M cell population)<sup>5</sup> or cortical mechanisms.<sup>6</sup>

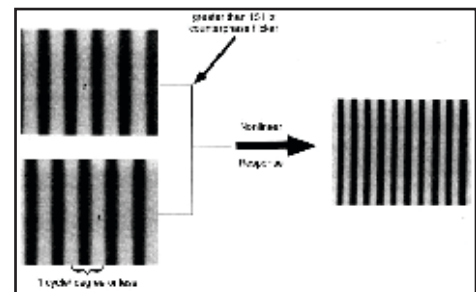


Fig 1. Frequency doubling illusion

### Frequency Doubling Perimeter:

Two generations of frequency doubling perimeters have been in place. The first generation FDP 1 tests 17-19 points within central field with a large 10° stimulus. The second generation FDP 2 (Humphrey Matrix) tests 54 points within 24° field with a relatively smaller 5° stimulus.

### FDP 1:

The frequency doubling perimeter measures contrast sensitivity to 0.25 cycles/degree vertical sine wave gratings that are counterphase flickered at 25 Hz. A large 10° square stimulus is used (compared to 0.43° for Goldmann Size III). This target is tolerant to substantial refractive error ( $\pm 6$  D). The stimulus is imaged at infinity and thus bifocals/ progressives are acceptable.

Frequency doubling perimeter consists of a video monitor, internal microprocessor, display panel for selection and monitoring test progress and a patient response button. It is lightweight (~ 9 kg) with an adjustable table



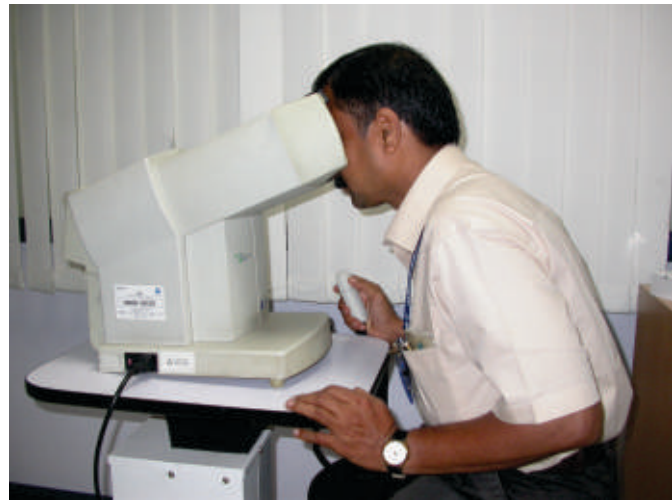

Fig 2. Frequency doubling perimeter (FDP 1)

height. There is no chin rest and a visor is kept over untested eye (Figure 2). The background luminance is much higher at  $100 \text{ cd/m}^2$  (compared to  $10 \text{ cd/m}^2$  for white on white perimetry)

The duration of stimulus is 720 ms, which consists of 160 ms ramping up of contrast, 400 ms at designated contrast and 160 ms of ramping down of contrast. A variable interval of upto 500 ms occurs between two stimuli. The ramping of contrast is done to avoid temporal transients at stimulus onset and offset that may affect response. A response is noted if it occurs between 100 ms to 1 second after stimulus presentation, otherwise it is noted as not seen.

### Test Layouts:

Two test layouts are available (Figure 3):

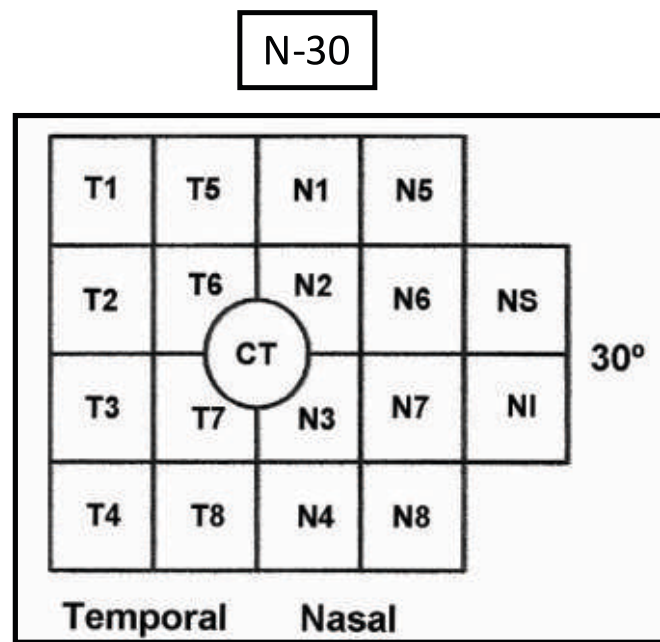
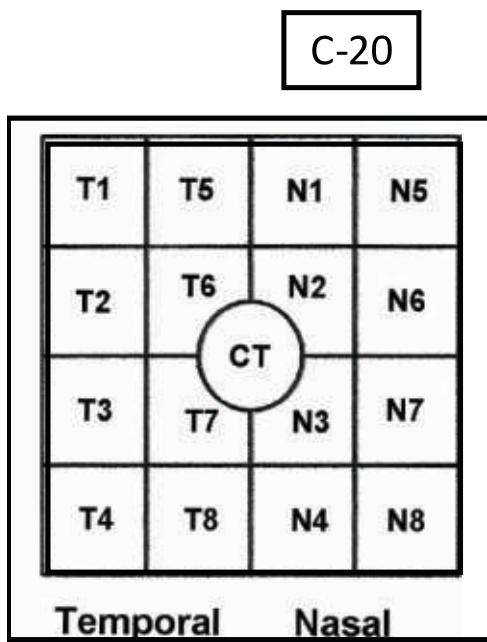


Fig 3. Test layouts for C-20 and N-30 strategies



**C-20:** Tests 17 locations in central 20 degrees, consisting of 16 square targets ( $10^\circ$  squares) and a central circular target ( $5^\circ$ ).

**N-30:** Tests 19 points. It tests additional two points in nasal field. These 2 points are tested after threshold has been evaluated for the 17 central locations by moving the fixation target  $10^\circ$  eccentrically.

Test protocols: Two full threshold and two suprathereshold (screening) tests are possible.

**Threshold tests** take an average of 4-5 minutes and use modified binary search (MOBS) staircase to determine threshold. In this, contrast of stimulus is raised if target is unseen and is decreased till unseen, similar to bracketing on white on white perimetry. Similar to white on white perimetry, false positive (response to zero contrast), false negative (failing to respond to stimuli of 100% contrast) and fixation losses (responding to a relatively smaller stimulus [ $1^\circ$ , 50% contrast] on blind spot; Heijl-Krakau method) are displayed via 'catch trials'.

**Suprathereshold tests** take an average of 45-90 seconds. The two suprathereshold tests available are denoted as C-20-1 and C-20-5 (Figure 4).

**C-20-1:** In this a stimulus with contrast which 99% of normal population can see is presented. If detected, no further testing is done at that point. If missed, the stimulus is presented again with same contrast and location is labeled  $P \geq 1\%$  if patient responds. If missed a second time, a stimulus with contrast which 99.5% of normal population can see is presented. If detected the location is labeled as  $P < 1\%$ . If missed a stimulus with maximum contrast (100%) is presented. If this stimulus is seen, the location is labeled as  $P < 0.5\%$  and if missed is labeled as 'not seen a maximum'. Earlier software versions labeled same as mild, moderate and severe losses rather than probability values.

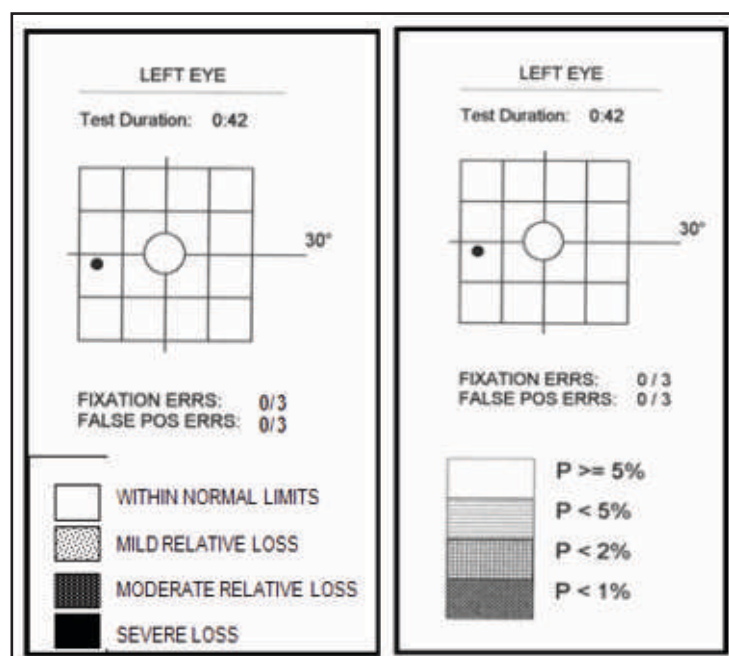



Fig 4. FDP C-20-1 (on left side) and C-20-5 (on right side)

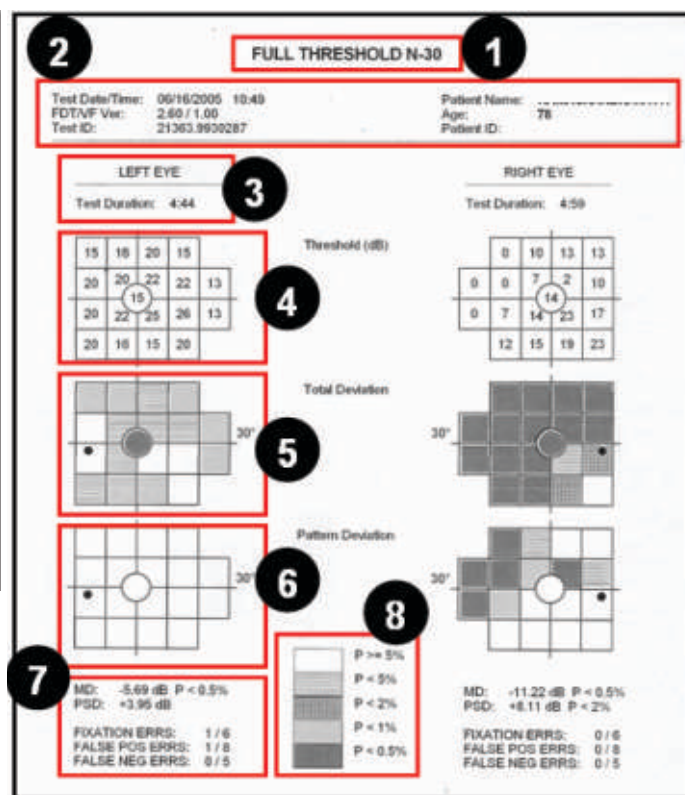
**C-20-5:** Similar to C-20-1 a stimulus with contrast which 95% of normal population can see is presented. If detected, no further testing is done at that point. If missed, the stimulus is presented again with same contrast and location is labeled  $P \geq 5\%$  if patient responds. If missed a second time, a stimulus with contrast which 98% of normal population can see is presented. If detected the location is labeled as  $P < 5\%$ . If missed a stimulus with 99% contrast is presented. If this stimulus is seen, the location is labeled as  $P < 2\%$  and if missed is labeled as  $P < 1\%$ .

### Interpreting the printout:

A typical screening C-20-1 printout and N-30 printout is as shown in Figure 5 and 6. For threshold tests, conventional limits of reliability (33%) are recommended. The MD and PSD are calculated in same manner as Humphrey field analyzer and similarly reflect the diffuse and localized sensitivity loss components. The threshold values in FDP are not comparable to those on conventional white on white perimetry.



- Fig 5: Printout FDP C-20-1 test showing
- 1) Name of test
  - 2) Test date and time
  - 3) Patient details (name, age, eye, test duration)
  - 4) Graphic representation of sensitivity values on grayscale levels
  - 5) Reliability indices
  - 6) Grayscale legends



- Fig 6: Printout FDP N-30 full threshold test showing
- 1) Name of test
  - 2) Test date and time with patient details (name, age, eye)
  - 3) Test duration
  - 4) Sensitivity values (in HVF equivalent decibel values)
  - 5) Total deviation plot
  - 6) Pattern deviation plot
  - 7) Reliability indices
  - 8) Grayscale legends

In screening tests, where only 3 catch trials occur and test locations are tested only once, it is recommended to repeat the test even if there is a single false positive response as they can greatly affect test results. (See clinical examples Figures 7 and 8)




Fig 7: A PACG patient with bipolar rim thinning showing corresponding field defects on C-20-1 and N-30 full threshold FDP and 24-2 Humphrey Visual Fields. Note the increased time taken to complete the suprathreshold C-20-1 test (2.03 minutes)

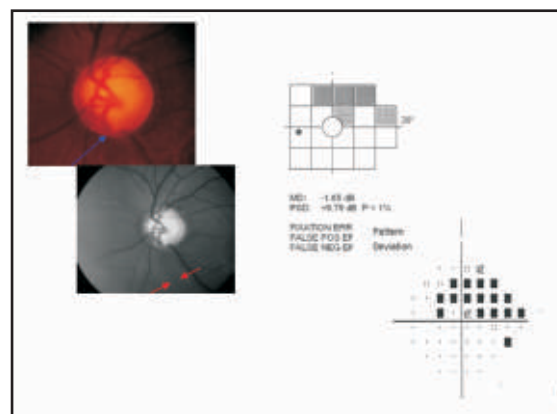


Fig 8: Glaucomatous optic disc with inferior rim thinning and nerve fibre layer defect. Note the corresponding defects on FDP and white on white perimetry

### Clinical correlation and evidence:

#### Detection of glaucoma:

The goal of screening is to detect disease with minimum of false positives. That is, the test should have high sensitivity (true positives) with a very high specificity (true negative). Note that the dimmest stimulus (at 99% contrast) in C-20-1 is the brightest stimulus tested in C-20-5. A very dark shaded area on C-20-5 will be lightly shaded on C-20-1. The C-20-1 test uses a conservative test strategy to maximize specificity. In other words, it is less likely to misclassify a normal visual field as abnormal. Also, it is more likely to miss out on subtle visual field loss. The high specificity (thereby reducing the number of falsely classified) makes this test more appropriate for mass screening purposes. Conversely the C-20-5 test has high sensitivity. In other words it is more likely to diagnose subtle visual field loss, making it more suitable for ophthalmic clinical settings.

Using C-20-1 various criteria have been described for screening. A criterion of presence of one or more abnormal points anywhere in field depressed to  $P < 1\%$  gives high sensitivity and high specificity. If we consider  $P < 0.5\%$  on similar lines, a higher specificity can be achieved. A criterion of two or more abnormal points anywhere in the field causes decrease in sensitivity although there is little change in specificity.

On similar lines, criteria for C-20-5 can be used. However in C-20-5 a higher screening sensitivity can be achieved as stimuli are presented at a contrast that 95% of age matched population is expected to see. However, the specificity is reduced as compared to C-20-1.

Scoring system on C-20-1 has been described by Patel et al.<sup>7</sup> This system gives more weightage to central points as compared to peripheral ones, given the increased variability in peripheral locations. Based on location, the outer 12 points are scored 1, inner 4 points are scored 3 and the central fixation is scored as 5. Each of these 17 points is further graded from 1 to 3 depending on defect depth. Normal points are scored 0, points with sensitivity at 1%, 0.5% and most severely involved points are scored 1, 2 and 3 respectively giving a final score from 0 (Normal) to 87. Overall, Patel scoring showed a sensitivity of over 80% and specificity of 93% for all glaucoma. In case of moderate and severe glaucoma, sensitivity rose to 95% and specificity to 93%. Individuals with more severe field losses took longer to finish the test and all subjects with normal fields completed the test in less than 90 seconds. An FDP score of 2 or more identified >80% of patients with glaucoma as defined by a defect on HVF. The authors concluded that an abnormal test can be identified by any defect in central 5 locations or two or more mild defects/ one moderate to severe defect in outer 12 points.

Cello et al.<sup>8</sup> evaluated the sensitivity and specificity of full threshold C-20 FDP in early ( $n = 85$ , MD on HVF  $\leq -6$  dB), moderate ( $n = 114$ , MD on HVF between -6 to -12 dB), or advanced ( $n = 31$ , MD on HVF -12 to -22 dB) glaucomatous visual field loss. Receiver operating curves showed sensitivity and specificity of 100% in diagnosing advanced glaucoma, 96% sensitivity and specificity for moderate glaucoma and approximately 85% sensitivity and 90% specificity for early glaucoma.

Both MD and PSD show a strong linear correlation to values obtained by white on white perimetry.<sup>9</sup> However the grading of severity of visual field loss on MD and PSD on FDP shows disagreements with those obtained on white on white perimetry.<sup>9</sup> FDP has been reported to have lesser test-retest variability in areas of relative sensitivity loss. In case of white on white perimetry, the variability increases as sensitivity decreases. Chauhan et al.<sup>10</sup> reported 120% variability in white on white perimetry as compared to <50% with FDP in locations with -20 dB loss in patients with glaucoma.

#### Glaucoma progression and non glaucomatous diseases

Staging of glaucomatous damage and assessing progression are hampered by coarse sampling grid of  $10^\circ$

square. Furthermore, there is a lack of a gold standard test to diagnose or monitor progression in early glaucoma. Interpretation of progression varies with the type of method used, some showing progression on SAP alone, others on FDP alone or on optic disc changes. The 'American Academy of Ophthalmology' in its 'Ophthalmic Technology Assessment (OTA)' concluded that FDP is "at best a weak predictor of further damage to optic nerve assessed by structure or worsening SAP".<sup>11</sup>

Hemianopic and quadrantanopic defects respecting the vertical midline in white on white perimetry may not be apparent with FDP. This may occur due to scattered field loss elsewhere in FDP or loss not respecting vertical midline. FDP is easier to perform and is less influenced by ocular media than SWAP. It is portable, relatively inexpensive, requires short testing time, is not affected by refractive blur upto 6D, pupil size (if >2 mm) does not affect the results and it requires minimal training. Besides it is not affected by ambient illumination and shows reasonably sensitivity and specificity to diagnose moderate and severe glaucomatous visual field defects. These attributes make FDP suitable for glaucoma screening.

### **FDP 2 (Humphrey Matrix):**

This second generation frequency doubling perimeter (Figure 9) uses a smaller stimulus size and thus greater test locations. This helps to pinpoint small localized defects and improves spatial resolution of field defects. To maintain similar sensitivity resolution and test retest variability, targets have higher spatial resolution (0.50 cycles/degrees) and lower temporal frequency (18 Hz or 12 Hz) as compared to FDP 1 (0.25 cycles/degrees, 25 Hz). Suprathreshold test takes around 1-2 minutes whereas threshold tests take 3-7 minutes.

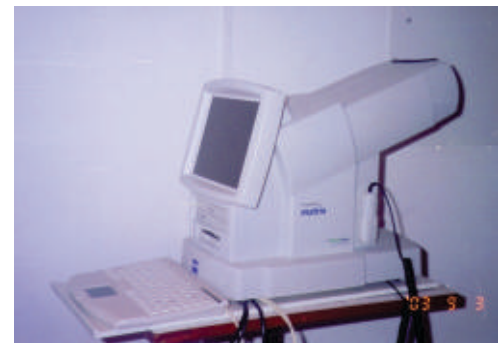

Fig 9. FDP 2 (Humphrey Matrix)

### **Test protocols (Figure 10):**

**Screening (Suprathreshold):** There are two suprathreshold tests.

**(1) N-30-5(-1):** Similar to original FDP

**(2) 24-2-5(-1):** Tests 55 points with 5° target

Additional screening test in Matrix as compared to FDP 1, which takes longer time than N-30 but gives more information on spatial localization of defects.

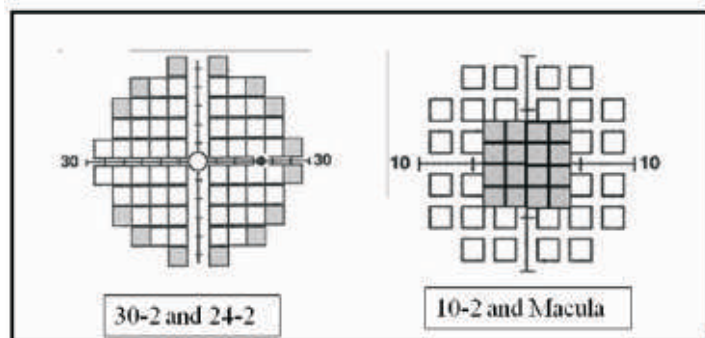


Fig 10. Test layouts on FDP 2 (Matrix)

**Threshold-** There are five threshold tests.

**(1) N-30-F:** It uses 19 point threshold test similar to original FDP 1, but uses 2 reversal MOBS (Modified Binary Search) instead of 4, making it more efficient and time saving.

**(2) 24-2**(tests 55 points)

**(3) 30-2**(tests 69 points) Both of these use a 5° x 5° square target with a spatial frequency of 0.50 cycles/degrees and temporal frequency of 18 Hz.

**(4) 10-2** (44 points)

**(5) Macula** (16 points)



Both of these use a  $2^\circ \times 2^\circ$  square target with a spatial frequency of 0.50 cycles/degrees and temporal frequency of 12Hz. However the smaller stimulus size and lower flicker rate precludes the appearance of frequency doubling.

Matrix threshold tests use test algorithm known as Zippy Estimation of Sequential Thresholds (ZEST), similar to SITA. In this, use of information gained from every response at a given location is used to determine final estimate of sensitivity thus reducing the test time.

### Interpreting the printout:

The test results are similar to standard automated perimetry. It includes grayscale, total and pattern deviation plots, visual field indices and reliability indices. (See clinical examples Figures 11 and 12)




Fig 11. Normal subject with normal SAP and FDP Matrix

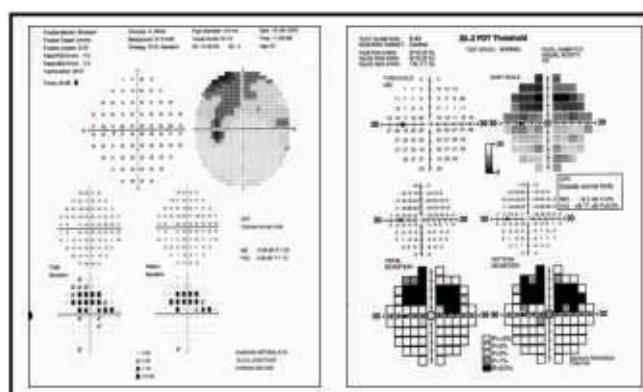


Fig 12. Subject with corresponding defects on SAP and FDP 2 (Matrix) in a glaucomatous optic disc with inferior rim thinning.

### Clinical correlation and evidence:

The results for threshold tests are compared to a normative database on over 270 individuals (18 to 85 years of age). The pattern of visual field loss resembles that on standard automated perimetry. An offset for targets on both sides of the vertical meridian gives improved ability to diagnose neurologic diseases.

Spry et al<sup>12</sup> evaluated Humphrey Matrix 24-2 thresholding program in 48 patients who were referred for suspected glaucoma. Of these, 31% were diagnosed as having glaucoma on optic nerve head appearance. The sensitivity and specificity levels for FDP and SWAP were noted as 100% and 26% and 80% and 52% respectively. The authors concluded that both tests yield similar results. Sakata LM et al<sup>13</sup> on basis of masked assessment of optic discs defined eyes as normal or glaucomatous. FDP Matrix was abnormal in 51% of eyes with glaucomatous optic disc and 11% in normals. SITA Standard was abnormal in 44% and 11% respectively. The difference was not statistically significant.

The 'American Academy of Ophthalmology' in its 'Ophthalmic Technology Assessment (OTA) concluded that "Matrix seems to perform as well as white on white perimetry but literature does not provide compelling for it to replace standard achromatic perimetry (SAP), nor its role in management of glaucoma defined adequately".<sup>11</sup>

## SHORT WAVELENGTH AUTOMATED PERIMETRY

Glaucoma patients as well as ocular hypertensives exhibit loss of sensitivity for short wavelength cone pathway in central visual field. SWAP isolates and measures the short wavelength sensitive pathway which requires a high luminance of 100 cd/m<sup>2</sup> broad spectrum yellow background (10 cd/m<sup>2</sup> for white on white perimetry) and a large diameter Goldmann Size V (1.7°) narrow band short wavelength (440 nm) stimulus of intensity 65 asb (as compared to 10000 asb for white on white perimetry). The stimulus duration is 200 ms. The blue sensitive ganglion cells comprise 5% of total RGC's and project to Koniocellular cells in lateral geniculate nucleus. Thus neural mechanisms underlying SWAP are sparse and uniquely designed to be specifically responsive to this type of stimulus.

The bright yellow background bleaches the red and green cone pigments and causes isolation of short wavelength sensitive pathway (Figure 13). However it still remains a basic threshold perimetry test. Detection of early field losses in SWAP has been reported. This may occur as it tests one type of RGC and so the defects may be manifest even if small numbers of these cells are affected due to the reduced redundancy of the system.

Full threshold SWAP takes a longer duration of nearly 12 minutes. This has been addressed by introduction of SITA SWAP which takes nearly 4 minutes. SWAP requires a pre adaptation to 3 minutes in yellow light. Patients are instructed that the stimulus may appear blurred. The test can be done in 30-2, 24-2 or 10-2 pattern.

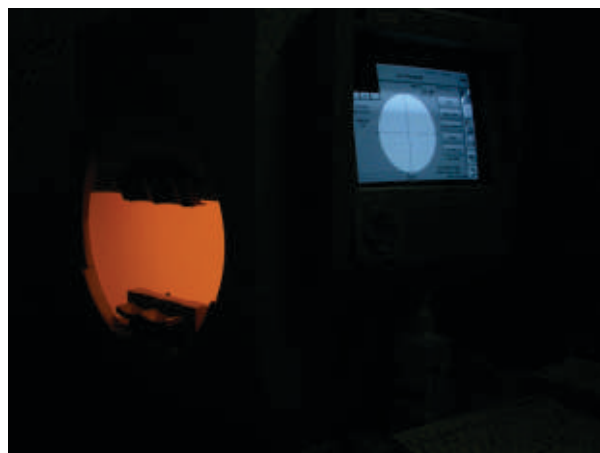


Fig 13. SWAP (note the intense yellow light)

## Interpreting the printout

A typical printout is shown below in Figure 14. On top are patient and test details. Similar to white on white perimetry, fixation losses, false positives and false negatives are displayed. Fixation losses can occur in SWAP as the stimulus is larger and patient with small physiological blind spots may show fixation losses despite steady fixation (Figure 14).

Noted below are sensitivity values in dB and grayscale representation of results, followed by total and pattern deviation probability plots and global indices. Note that the grayscale in SWAP appears darker than white on white perimetry for the same patient (Figure 15). This occurs as raw threshold values for SWAP are much lower than white on white perimetry (Figure 16) even in healthy eyes and the grayscale is not optimized for its dynamic range. Therefore the grayscale is best ignored in SWAP. It is better to rely on total and pattern deviation plots and global indices (Figure 16). Similar to white on white perimetry, the total deviation




Fig 14. A typical SITA-SWAP printout (for details see text above). Note the fixation losses.

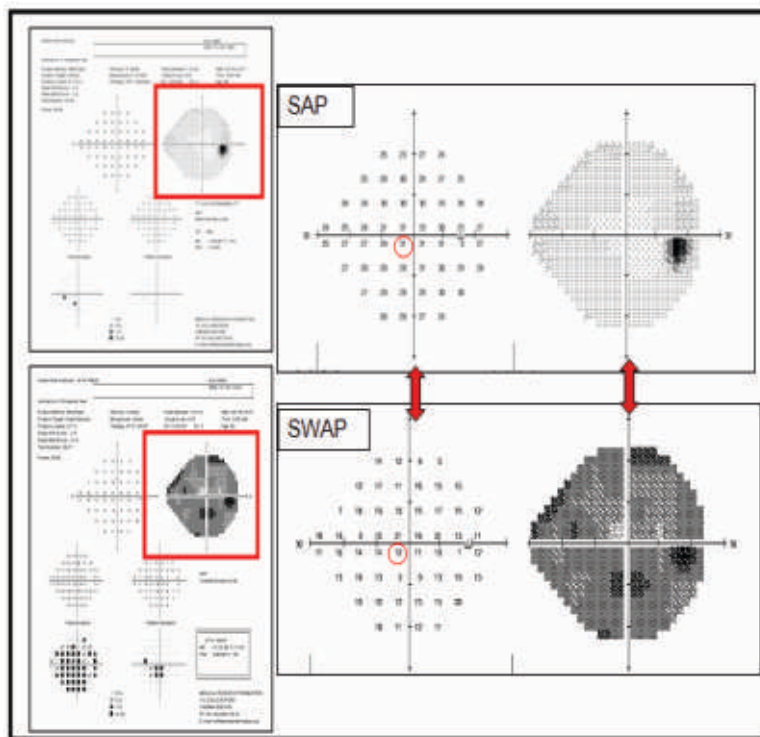


Fig 15. Corresponding SAP and SITA-SWAP of the same patient. Note that the grayscale appears much darker in SWAP and raw thresholds are much lower in SWAP as compared to SAP.




Fig 16. For clinical interpretation, the grayscale is disregarded. The total and pattern deviation plots and visual field indices are used clinically.

plots in dB and probability values are displayed and pattern deviation plot corrects for generalized depression to reveal localized field losses.

Similar to white on white perimetry, SWAP full threshold global indices are given in a box (MD, PSD, SF, CPSD) along with glaucoma hemifield test result. SITA SWAP displays MD and PSD values. Glaucoma hemifield test results are displayed as outside normal limits, borderline, general depression of sensitivity, abnormally high sensitivity or within normal limits.

## Clinical correlation and evidence:

SWAP defects appear earlier than white on white perimetry. The loss can be localized or diffuse. Sample [PA](#) et al<sup>14</sup> compared SWAP, C-20 FDP and motion-automated perimetry in 136 eyes with glaucomatous optic neuropathy (assessment of stereophotographs, n=136) and ocular hypertension (IOP  $\geq$  23 mm Hg on at least two occasions and normal optic disc stereophotographs, n=37). Abnormalities in visual fields for eyes with glaucomatous optic neuropathy were identified in 46% with standard perimetry, 61% with SWAP, 70% with FDP, and 52% with motion-automated perimetry. In ocular hypertensive eyes, standard perimetry was abnormal in 5%, SWAP in 22%, FDP in 46%, and motion in 30%. Only 30% (11/37) of the ocular hypertensive eyes showed no deficits compared with 71% (20/28) of control eyes ( $P < 0.001$ ). Horn et al<sup>15</sup> in a cross sectional study used FDP (C-20-5) and SWAP (Octopus 101, G2) in 43 subjects with preperimetric glaucoma (glaucomatous optic disc atrophy and no visual field defect in standard perimetry) and 26 with perimetric open angle glaucoma (glaucomatous optic disc and visual field defect in standard perimetry). The AUC for SWAP was 0.704 for preperimetric and 0.96 for perimetric glaucoma. The combination of SWAP and FDP increased AUC marginally for both preperimetric and perimetric glaucoma.



Leeprechanon N et al<sup>16</sup> evaluated 42 patients with preperimetric disc damage and 35 normals in a prospective case control study. Early glaucoma was defined as glaucomatous disc changes with changes in either HRT or OCT with normal SAP. The contralateral eye had abnormal SAP results. All patients underwent SWAP full threshold and FDP (Matrix). Defects on TD and PSD plots were detected more frequently on FDP in the glaucoma group and was significant for  $P < 0.01$  defects on pattern deviation plot ( $P = 0.024$ ). Best discrimination was seen for SWAP MD (Area under ROC 0.74) and FDP PSD (Area under ROC 0.67) demonstrating only fair discriminatory ability to distinguish normals from preperimetric glaucoma. Ferreras A et al<sup>17</sup> evaluated full threshold FDP and SWAP in 278 subjects including 109 preperimetric (abnormal optic disc or RNFL [HRT II, GDx VCC, OCT 3000 or stereophotographs] or both with normal SAP), 71 glaucoma (glaucomatous optic nerves and abnormal SAP) and 98 normals). The sensitivity of FDP and SWAP varied with the criteria of structural damage from 20% to 100 %. With worsening structural abnormalities, the sensitivity of FDP and SWAP increased. Both FDP and SWAP were abnormal in one third of eyes with glaucomatous appearing optic nerves.

SWAP defects typically involve a greater area of visual field and may be predictive of future visual field loss.<sup>11</sup> Polo et al<sup>18</sup> performed SWAP 30-2 in 160 ocular hypertensive subjects (IOP > 21 mm Hg, normal standard automated perimetry). Subjects underwent RNFL photography and SWAP at baseline. At the beginning, 77 eyes showed RNFL losses (48%), and 58 eyes showed abnormalities in SWAP (36%). At the end of 3 years, SAP defects developed in 19% with abnormal SWAP at baseline as opposed to 4% with normal SWAP at baseline. SAP defects developed in 18% of eyes with abnormal RNFL at baseline as compared to 1% with normal baseline RNFL. Girkin CA et al<sup>19</sup> compared progression in 24-2 full threshold SWAP and SAP in eyes with progressive glaucomatous changes of the optic disc detected by serial stereophotographs. The mean follow up was 4.1 years. Progression was noted in 22 out of 47 eyes on stereophotographs. Of these, progression on SWAP was noted in 12 (55%) and on SAP in 7 (32%) eyes. SWAP was better in discriminating eyes with optic disc progression than without progression (AUC 0.773 for SWAP versus 0.659 for SAP;  $P = 0.04$ ). These studies suggest that abnormal SWAP results may be a predictor of subsequent conversion from normal to abnormal SAP.

However, SWAP is limited by large variability including high short and long term fluctuation. SWAP defects progress faster than white on white perimetry. SWAP is limited by the dynamic range of the perimeter. As noted, the raw thresholds are low to start with even in healthy eyes. Thus SWAP is of limited use in moderate and advanced glaucoma where low raw thresholds may not be discernible and it is recommended to have standard white on white perimetry. SITA SWAP appears to be as useful as full threshold SWAP.

Thus SWAP is mainly useful in

- 1) Glaucoma suspects with a normal white on white perimetry
- 2) Ocular hypertension
- 3) Glaucoma subjects with mild visual field loss

## CONCLUSIONS

Advances in technology and analytic tools over the last decade has given us varied ways to assess visual function in glaucoma. However definitive guidance on diagnosis and progression over time is still warranted.



## References

1. Sample PA, Bosworth CF, Blumenthal EZ et al. Visual function specific perimetry for indirect comparison of different ganglion cell populations in glaucoma. *Invest Ophthalmol Vis Sci*. 2000;41:1783-1790.
2. Lesya MS, Young HW. Glaucomatous visual field loss. In Daniel M Albert, Joan W Miller editors. *Principles and Practice of Ophthalmology*. Elsevier; 2008. P 2508.
3. Kelly DH. Frequency doubling in visual responses. *J Opt Soc Am* 1966;56:1628-33.
4. Kelly DH. Nonlinear visual responses to flickering sinusoidal gratings. *J Opt Soc Am* 1981;71:1051-5.
5. Maddess T, Henry GH. Performance of nonlinear visual units in ocular hypertension and glaucoma. *Clin Vision Sci* 1992;7:371-83.
6. Anderson AJ, Johnson CA. Mechanisms isolated by frequency doubling technology perimetry. *Invest Ophthalmol Vis Sci* 2002;43:398-401.
7. Patel S, Friedman D, Varadkar P, Robin A. Algorithm for interpreting results of FDP. *Ophthalmol* 2000;129:323-327.
8. Cello KE, Nelson-Quigg JM, Johnson CA. FDP perimetry for detection of glaucomatous visual field loss. *Am J Ophthalmol* 2000;129:314-322.
9. Sponsel WE, Santiago A, Yolanda T et al. Clinical classification of glaucomatous visual field loss by frequency doubling perimetry. *Am J Ophthalmol* 1998;125:830-6.
10. Chauhan BC, Johnson CA. Test retest variability of FDP and conventional perimetry in glaucoma patients and normal subjects. *Invest Ophthalmol Vis Sci* 1999;40:648-56.
11. Henry D. Jampel et al. OTA. Assessment of Visual Function in Glaucoma. A Report by the American Academy of Ophthalmology. *Ophthalmology* 2011;118:986-1002
12. Spry PG, Hussin HM, Sparrow JM. Clinical evaluation of frequency doubling technology perimetry using the Humphrey Matrix 24-2 threshold strategy. *Br J Ophthalmol* 2005;89:1031-5.
13. Sakata LM, Deleon-Ortega J, Arthur SN, et al. Detecting visual function abnormalities using the Swedish interactive threshold algorithm and matrix perimetry in eyes with glaucomatous appearance of the optic disc. *Arch Ophthalmol* 2007;125:340-5.
14. Sample PA, Bosworth CF, Blumenthal EZ, et al. Visual function specific perimetry for indirect comparison of different ganglion cell populations in glaucoma. *Invest Ophthalmol Vis Sci* 2000;41:1783-90.
15. Horn FK, Brenning A, Junemann AG et al. Glaucoma detection with frequency doubling perimetry and short wavelength perimetry. *J Glaucoma* 2007;16:363-71.
16. Leeprechanon N, Giaconi JA, Manassakorn A, et al. Frequency doubling perimetry and short-wavelength automated perimetry to detect early glaucoma. *Ophthalmology* 2007;114:931-7.
17. Ferreras A, Polo V, Larrosa JM, et al. Can frequency-doubling technology and short-wavelength automated perimetries detect visual field defects before standard automated perimetry in patients with preperimetric glaucoma? *J Glaucoma* 2007; 16:372-83.
18. Polo V, Larrosa JM, Pinilla I et al. Predictive value of short-wavelength automated perimetry: a 3-year follow-up study. *Ophthalmology*. 2002 Apr;109(4):761-5.
19. Girkin CA, Emdadi A, Sample PA et al. Short-wavelength automated perimetry and standard perimetry in the detection of progressive optic disc cupping. *Arch Ophthalmol*. 2000;118:1231-1236.

# OPTIC DISC PHOTOGRAPHY

Glaucoma is a progressive optic neuropathy and hence examination and documentation of the Optic nerve is a cornerstone of clinical evaluation of a glaucoma patient or suspect. Photography of the optic disc has been in practice for several decades. Initially, using conventional photos and, more recently, digital imaging.

## Technique for Optic disc Photography

Stereophotos of the optic disc are best suited for evaluation and documentation as baseline for future comparisons to determine progression. Stereoscopic photographs consist of image pairs obtained simultaneously or sequentially with a spatial shift that provides retinal image disparity. This image disparity allows perception of cup depth and excavation and rim contour. A standard fundus camera can be used to obtain sequential optic nerve images from two different angles by varying the position of the camera itself or by using an Allen Stereo Separator. Simultaneous stereophotos require a special camera with beam-splitting prisms to image the optic nerve. Photos need to be viewed using a stereo-viewer. Alternative newer technology using a 3D monitor and polarized glasses is now available. Although both methods can provide excellent stereoscopic images. The sequential method is inferior for the comparison of photographs over time because it required the introduction of disparity via manual shift of the camera position. Several studies have reported that reproducibility of stereoscopic information and disc assessment is better with simultaneous compared to sequential stereophotography.

The photos need to be centered on the optic disc and preferable 15 degree views so that the details appear magnified.

Along with colour stereophotos there should be red free photos as nerve fiber layer defects are better viewed. The red free photo may be a 30 degree view to include the vascular arcades and macular area.

## Intra and Inter Observer reproducibility in Photograph Grading

Few studies have investigated the degree to which masked observers agree in their assessment of photographs. Intra-observer reproducibility ( $\kappa=0.69-0.96$ ) is consistently higher than inter-observer reproducibility ( $\kappa=0.20-0.84$ ) in studies evaluating agreement among observers when estimating optic disc parameters and discriminating glaucoma eyes from normal healthy eyes with stereoscopic photographs. In general, high inter-observer reproducibility values are obtained when standardized methods are used. Substantial variability exists in the interpretation of optic disc change, even with expert observers, with  $\kappa$  values ranging from 0.50-0.96 for intra-observer agreement and from 0.55-0.81 for inter-observer agreement. The inter-observer reproducibility in EGPS ranged between 0.45 and 0.75, while intra-observer reproducibility was 0.79-1.00.

When looking for progression, imaging parameters, such as focus, stereopsis, quality, magnification, and type of camera used, can influence reproducibility. Availability of clear-cut definition for progression and experience of the reader may also affect the results.

## Advantages of Photography over other Imaging Technology

1. the photos may be compared even years later and may be used even for comparison during clinical examination besides comparing with more recent photos.
2. imaging devices do have problems in certain situations such as high astigmatism, poor media, large peripapillary atrophy, very large and small disc sizes etc. Photographs may be better suited for progression evaluation in these situations.

3. there have been studies showing experts using stereo-photos being able to pick up progression as well as other devices.

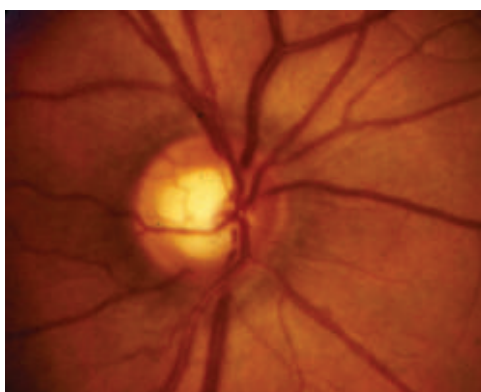
### Disadvantages of Photography

1. remains subjective and untrained persons perform less efficiently than trained persons.
2. sometimes judgment of pallor may be variable depending on other factors.

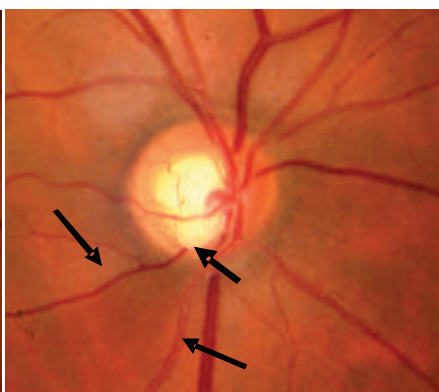
### Monitoring Progression with Optic Disc Photographs

Studies that used optic disc and retinal nerve fiber layer (RNFL) photography have shown that an increase in cup area or thinning of the neuroretinal rim, emergence of focal rim notch or splinter haemorrhage at the disc margin, and thinning of the RNFL, may all precede glaucomatous visual field changes as tested on achromatic perimetry. Investigations exploring the relationship between optic disc appearance and visual function measurements, both cross-sectionally and longitudinally, have provided additional evidence that progressive optic disc and RNFL damage can be detected with photographic data. These studies suggest that quantitative changes in visual function likely to have predictable qualitative analogues in optic disc photographs. In the Ocular hypertension Treatment Study, 55% of subjects converted to POAG based on changes in the optic disc only, as determined by optic disc photographs.

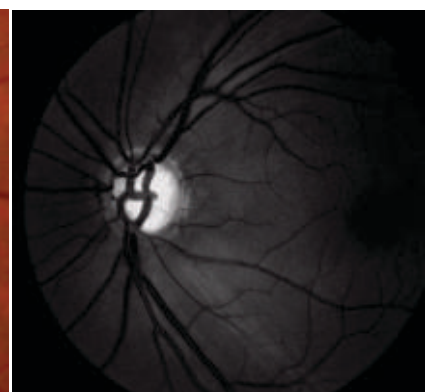
One study reported the use of the flicker method (stereochronoscopy) for longitudinal evaluation of monocular colour disc photos. In this method the initial baseline photograph and the follow up photograph are projected in a fast alternating sequence, the difference between the two would be very easy to identify in this fashion. The changes identified by the flicker method were usually visible with conventional evaluation as well, once attention was directed to the altered area. While in this study flicker was very sensitive in detecting change, in the EMGT study, only 7% of all 255 patients showed progressive changes in their optic disc during the entire six years of follow up (compared to progression of visual fields in 53% of patients). For the flicker method to be effective all the photographs need to be taken in the same angle. If this is not the case, parallax effect will cause apparent shifts that may be interpreted as change.



Baseline Photograph showing normal disc



Follow up Photograph taken 5 months later, showing inferior notch and NFL defects



Red Free Photography showing inferior NFL defect

## References

1. Abrams LS, Scott IU, Spaeth GL, Quigley HA, Varma R: Agreement among optometrists, Ophthalmologists, and residents in evaluating the optic disc for glaucoma. *Ophthalmology* 1194;101:1662-1667.
2. Airaksinen PJ, Drance SM, Douglas GR, Schulzer M, Wijsman K: Visual field and retinal nerve fiber layer comparisons in glaucoma. *Arch Ophthalmol* 1985;103:205-207.
3. Airaksinen PJ, Mustonen E, Alanko HI: Optic disc haemorrhages precede retinal nerve fiber layer defects in Ocular Hypertension. *Acta Ophthalmol (Kbh)* 1981;59:627-641.
4. Airaksinen PJ, Tuulonen A, Alanko HI: Rate and pattern of neuroretinal rim area decrease in ocular hypertension and glaucoma. *Acta Ophthalmol* 1992;110:206-210.
5. Burgoyne CF, Quigley HA, Varma R: Comparison of clinical judgment with digitized image analysis in the detection of induced optic disc change in monkey eyes. *Am J Ophthalmol* 1995;120:176-183.
6. Caprioli J: Clinical evaluation of the optic nerve in glaucoma. *Trans Am Ophthalmol Soc* 1994;92:589-641.2.
7. Caprioli J, Prum B, Zeyen T: Comparison of methods to evaluate the optic nerve head and nerve fiber layer for glaucomatous change. *Am J Ophthalmol* 1996;121:659-667.
8. Coleman AL, Sommer A, Enger C, Knopf HL, Stamper RL, Minckler DS: Inter observer and intraobserver variability in the detection of glaucomatous progression of the optic disc. *J Glaucoma* 1996;5:384-389.
9. Feuer WJ, Parrish RK II, Schiffman JC, Anderson DR, Budenz DL, Wells MC, Hess DJ, Kass MA, Gordon MO: The Ocular Hypertension Treatment Study: reproducibility of cup/disc ratio measurements over time at an optic disc reading center. *Am J Ophthalmol* 2002;133:19-28.
10. Kass MA, Heuer DK, Higginbotham EJ, Johnson CA, Keltner JL, Miller JP, Parrish RK II, Wilson MR, Gordon MO: The Ocular Hypertension Treatment Study: a randomized trial determines that topical ocular hypotensive medication delays or prevents the onset of primary open-angle glaucoma. *Arch Ophthalmol* 2003;120:701-713; discussion 829-730.
11. Krohn MA, Keltner JL, Johnson CA: Comparison of photographic techniques and films used in stereophotogrammetry of the optic disc. *Am J Ophthalmol* 1979;88:859-863.
12. Litcher PR: Variability of expert observer in evaluating the optic disc. *Trans Am Ophthalmol Soc*. 1977;74:532-572.
13. O'Connor DJ, Zeyen T, Caprioli J: Comparison of methods to detect glaucomatous optic nerve damage. *Ophthalmology* 1993;100:1498-1503.
14. Odberg T, Riise D: Early diagnosis of glaucoma. The value of successive stereophotography of the optic disc. *Acta Ophthalmol. (Kbh)* 1985;63:257-263.
15. Quigley HA, Katz J, Derick RJ, Gilbert D, Sommer A: An evaluation of the optic disc and nerve fiber layer examination in monitoring progression of early glaucoma damage. *Ophthalmology* 1992;99:19-28.
16. Shuttleworth GN, Khong CH, Diamond JP: A new digital optic disc stereo camera: intraobserver and inter observer repeatability of optic disc measurements. *Br J Ophthalmol* 2000;84:403-407.
17. Tielsch JM, Katz J, Quigley HA, Miller NR, Sommer A: Intraobserver and interobserver agreement in measurement of optic disc characteristics. *Ophthalmology* 1988;95:350-356.
18. Tuulonen A, Airaksinen PJ: Initial glaucomatous optic disc and retinal nerve fiber layer abnormalities and their progression. *Am J Ophthalmol* 1991;111:485-490.
19. Varma R, Steinmann WC, Scott IU: Expert agreement in evaluating the optic disc for glaucoma. *Ophthalmology* 1992;99:215-221.
20. Zeyen TG, Caprioli J: Progression of disc and field damage in early glaucoma. *Arch Ophthalmol* 1993;111:62-65.
21. Zeyen T, Miglioni S, Pfeiffer N, Cunha-Vaz J, Adamsons I: Reproducibility of evaluation of optic disc change for glaucoma with stereo optic disc photographs. *Ophthalmology* 2003;110:340-344.



# CONFOCAL LASER SCANNING TOMOGRAPHY PRINCIPLES AND CLINICAL UTILITY

## Introduction:

The optic disc is an important site of glaucomatous damage. In addition this is accompanied by changes in the retinal nerve fiber layer and adjacent peripapillary tissues. Clinical examination of the optic nerve remains an important tool in the day to day diagnosis and management of subjects with optic neuropathy. Stereoscopic magnified evaluation of the optic nerve has become the norm of clinical optic disc examination. Clinical notes and drawings of the optic nerve has been followed for several decades. Optic nerve photography became adopted as a tool for documentation and comparison of disc photographs which complimented the clinical stereoscopic evaluation and the disc drawings. Stereodisc photography using cameras specially designed for it was also adopted though not universally. Subjective assessment both clinically and on photography is an important consideration. A shift in techniques and technology towards a more objective and accurate documentation system which allows for follow up over time was an important goal. This was the basis of the development of several objective and accurate imaging tools amongst which is the confocal scanning laser ophthalmoscope also known as the Heidelberg Retina Tomograph.

## Confocal Sanning Laser Tomography.

**Basis of Function:** The Heidelberg Retina Tomograph is a scanning laser ophthalmoscope specially designed to acquire three dimensional images of the optic nerve head, retinal nerve fiber layer and posterior pole. A rapid scanning 670nm diode laser is used to acquire images, without mydriasis. Images are obtained non invasively, at low illumination and rapidly.

The HRT II and HRT III acquire reflectance images (16-64) to a depth of 4 mm. These are consecutive and equidistant two dimensional optical section images. Each successive scan plane is 0.0625 mm deeper. Thus if scanning of 1 mm. depth is needed, 16 imaging planes will be scanned. If it is 2 mm. depth then there will be 32 imaging planes and so on to a maximum depth of 4 mm. These are joined together to provide a three dimensional contour map of the optic disc surface. An area of 15deg by 15 deg is imaged. The topographical image consists of more than 147000 independant local height measurements. The images obtained have high spatial resolution. A lateral resolution of 10  $\mu$ m is achieved. Three scans are included for analysis and storage from the prescans. The software automatically aligns these scans and averages the values to create the mean topography scan for the individual.

**Method of Imaging Optic Disc:** The patient is asked to sit in front of the instrument and to look at the internal fixation target. (Fig. 1) The actual imaging may take place in 10 seconds and in practice the eye may be imaged in less than a minute. The corneal curvature has to be entered for the subject and the manifest refraction. A cylinder of more than 1 dioptre refractive error is corrected by attaching cylindrical lenses to the HRT. Each scan gives a standard deviation value. A value of under 20  $\mu$ m indicates an excellent image, 20-30  $\mu$ m a very good image and 30-40  $\mu$ m an acceptable image.

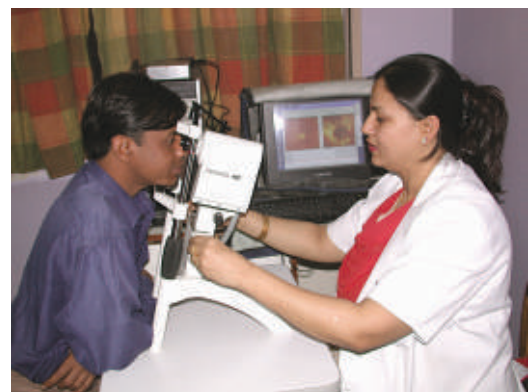

Fig 1. Showing the operator and subject using the Heidelberg Retina Tomograph.

Once the image has been obtained the contour line should be drawn. This identifies the margin of the optic disc. The reflectance image may be used for this. When in doubt about the exact border of the optic disc, one may identify the contour of the blood vessels, the peripapillary atrophy, and other visual cues. It is also helpful to visualise the colour optic disc photograph (Fig. 2) to delineate the margin with the help of the drawing tool provided. This is the most important manual part of the imaging. Once this is done the several parameters of the image will automatically be generated. Once the contour line is done, the software automatically creates a reference plane, (Fig 3) parallel to the peripapillary retinal surface and located 50  $\mu\text{m}$  below the retinal surface as measured along the contour line in the papillomacular bundle (350deg. to 356deg). This reference line serves as the base with which the height of the retinal nerve fiber layer is measured along the retinal surface all around the disc along the contour line. In addition the reference plane serves to separate the disc into the rim and the cup. The colour coded optic disc image provides for identification of the rim (green), rim slope (blue) and cup (red).

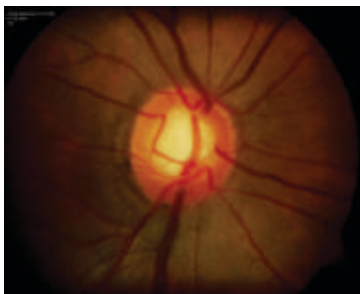


Fig. 2. Optic disc of the subject for whom the CLSO images are shown.

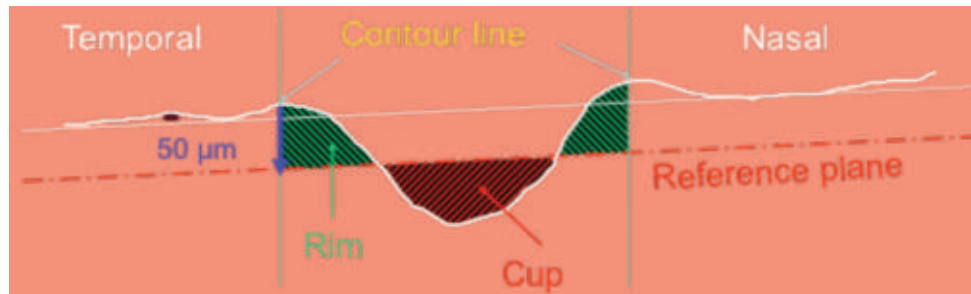


Fig. 3. Reference plane is located 50  $\mu\text{m}$  below the mean height of the retinal surface along the contour line, between 350deg-356 deg. (papillo-macular bundle). Volume enclosed by the contour line and located above the reference plane is the rim. Below is the cup.

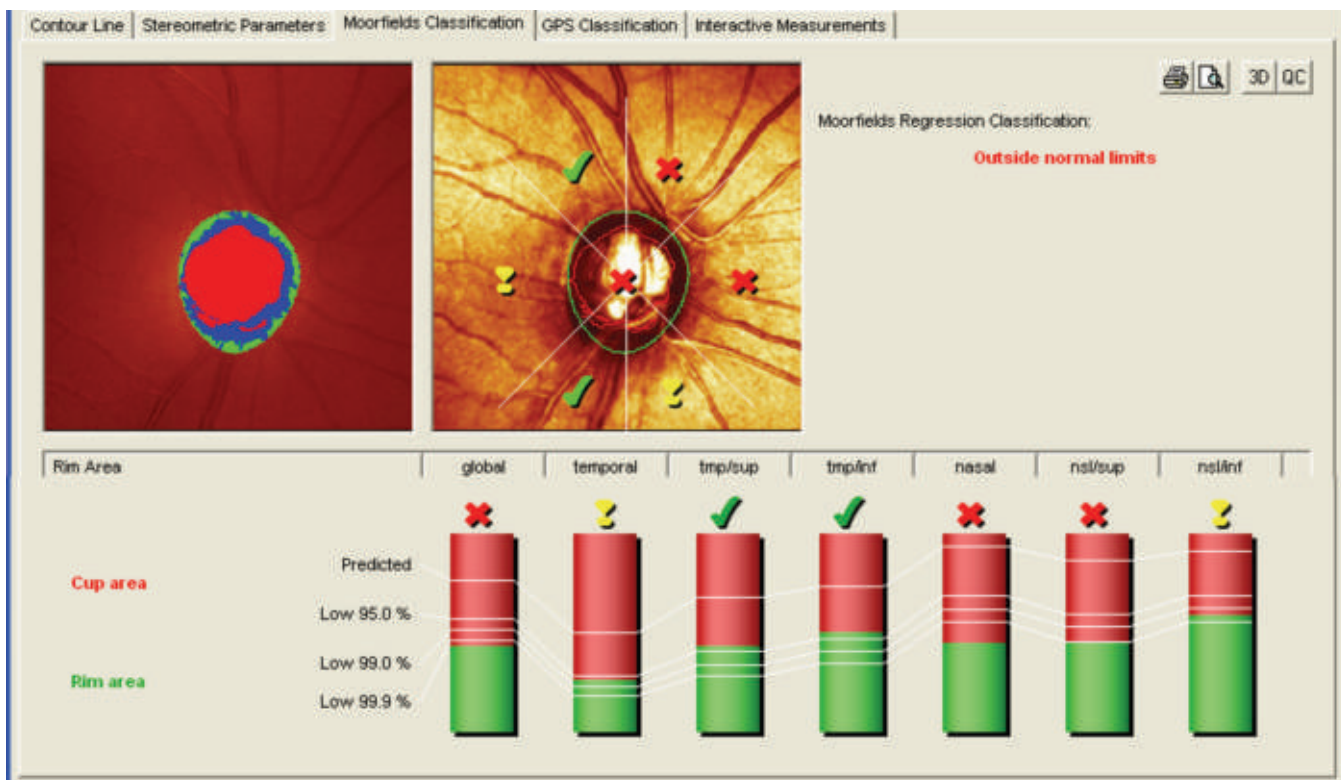


Fig. 4. Showing colour coding of neuroretinal rim and cup, optic disc segments on CLSO and Moorfields Regression Classification.

**Parameters.** The morphometric parameters besides the optic disc area include cup area, cup disc area ratio, rim area, cup volume, cup depth, retinal nerve fiber layer thickness and cross sectional retinal nerve fiber layer area. These parameters are available for the entire optic disc (global) and for the different segments of the optic disc. The optic disc in the HRT imaging can be for purposes of measurements, analysis and follow up be segmented in various ways. The most common is in 6 segments: superotemporal, temporal, infero-temporal, infero-nasal, nasal and supero-nasal. (Fig 4)

A selection of the measurements that are generated by the HRT are as follows.

1. Disc Area (mm<sup>2</sup>). This is the area bounded by the contour line, indicating the area of the optic disc.
2. Cup Area (mm<sup>2</sup>). This is the area of the optic disc cupping and is seen as the area enclosed by the contour line, which is located beneath the reference plane. It appears as a red overlay on the topography image.
3. Rim area (mm<sup>2</sup>). This is the area of the neuroretinal rim and is seen as the area enclosed by the contour line, which is located above the reference plane. It appears as either blue or green on the topography image. (blue-sloping and green- stable neuroretinal rim)
4. Cup Volume. The volume of optic disc cupping, defined as the volume enclosed by the contour line and located above the reference plane.
5. Cup/Disc Area Ratio: Ratio of area of optic disc cupping to area of the optic disc.
6. Linear Cup/Disc Ratio: The average cup disc diameter ratio calculated as the square root of the cup/disc area ratio.
7. Mean Retinal Nerve Fiber Layer Thickness: The mean thickness of the retinal nerve fiber layer measured along the contour line, and measured relative to the reference plane.
8. RNFL Cross Section Area (mm<sup>2</sup>) This is the total cross-sectional area of the retinal nerve fiber layer along the contour line, and measured relative to the reference plane.

In the print out, the parameters from the normative database of the particular ethnic group (Caucasians, African Americans and Indians) are given and compared with values obtained in the particular patient. When the parameters are different from the normative values, significance values are highlighted helping the clinicians in the interpretation.

**Moorfield Regression:** The Moorfields regression was derived at Moorfields Hospital on normal subjects. The regression has as its basis the log of the rim area plotted against the disc area. Thus if for a particular disc, the rim area/disc area ratio is less than expected in a normal population, then one may suspect that the patient has glaucoma. The Moorfields regression analysis may also be performed for the different segments of the optic disc. The upper limit of the disc size to be acceptable for the MRA was about 2.8 mm<sup>2</sup>. However the new databases may enable the MRA to be acceptable for disc sizes between 1 to 3.6 (caucasian database). It may not be utilised or only with caution in discs smaller or larger than mentioned. The Moorfields regression is represented in a bar form representing the rim as green and the red as the cup. There are three lines that cross the red green bar. The predicted line, which is the average or predicted relationship between log neuroretinal rim area and optic disc area. The lower three lines represent the lower 95%, 99.0% and 99.9% prediction intervals for the same relationship. Thus for the 95.0% prediction interval, 95.0% of normal eyes would be expected to have a neuroretinal rim area above that interval line. The same principal would apply for the lines representing 99.0% and 99.9% prediction intervals. (Fig.4)

**Bilateral Print Out.** An informational print out of both eyes is now available. It includes information about the patient and the disc area. It further includes the linear cup disc ratio, cup shape measure, rim area, rim volume,



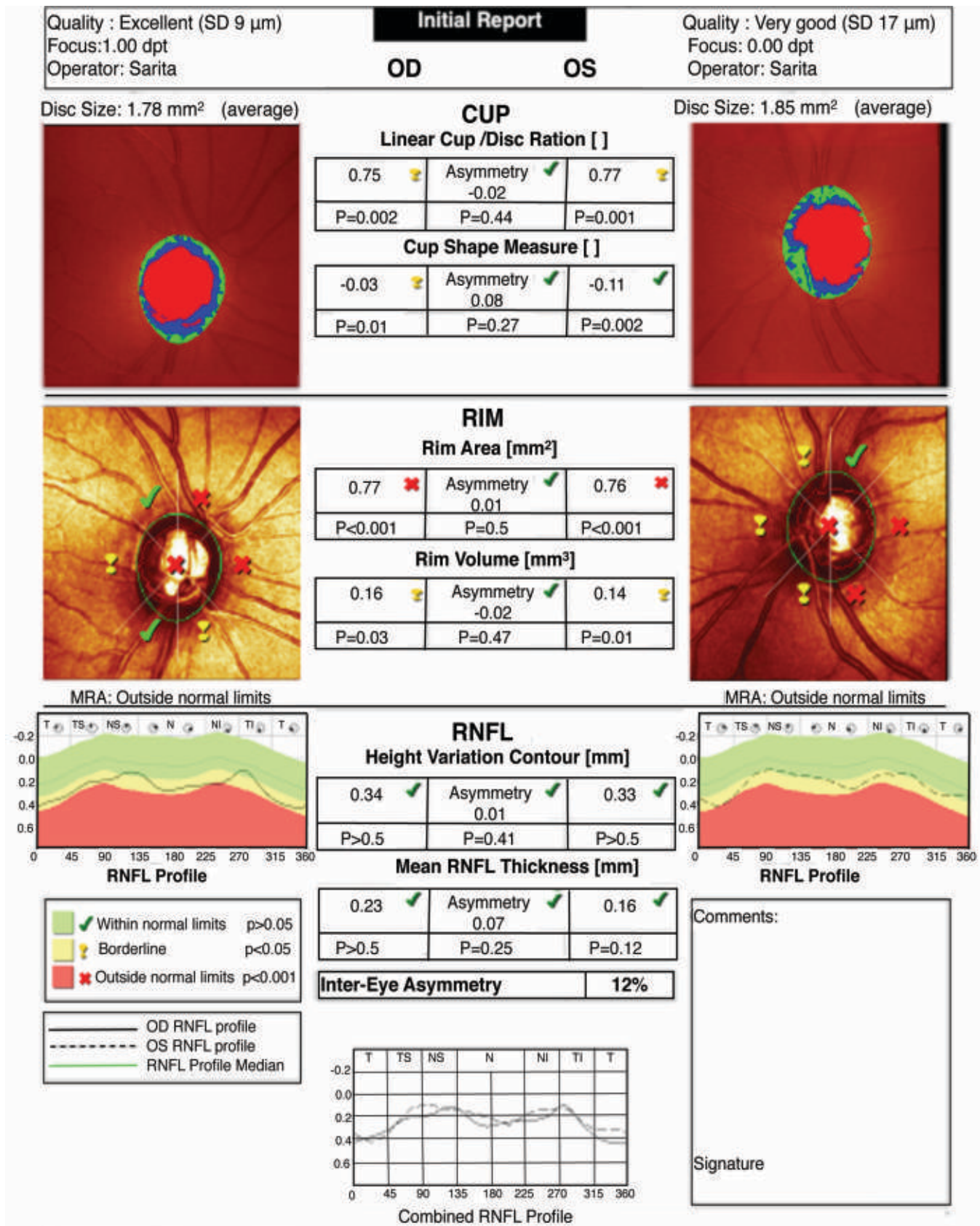


Fig 5. Showing bilateral print out.



height variation contour and retinal nerve fiber layer thickness. Values are provided for each eye, including the asymmetry by subtracting the left from the right eye values. Significance values as comparison with normative data and significance values for asymmetry are also provided. (Fig 5)

**Progression Analysis.** Progression is the hallmark of glaucomatous disease and plays an important role in defining the further management of glaucoma subjects. Height measurements taken at pixels are used to compare change between baseline and follow up examinations. Probability and significance is arrived at by comparing the baseline with the follow up measurements. When the error probability of the height change is less than 5% for rejecting the equal variances hypothesis it indicates a significant change at the corresponding location. For topographic change analysis one baseline and 2 follow up examinations are required. In the image for topographic change analysis, there is a change map, a probability map and a significance map. Areas in red are those which show a depression and areas in green are those which show elevation. The exact values in area and volume and the change can be obtained by pressing the mouse at the location of change. (Fig 6) A cluster change graph may also be obtained which shows the area along the Y axis on the left, the volume on the Y axis on the right and the time interval and examination date on the X axis. A change in the normalised values of stereometric parameters vs. time may also be displayed in a graph for different segments.

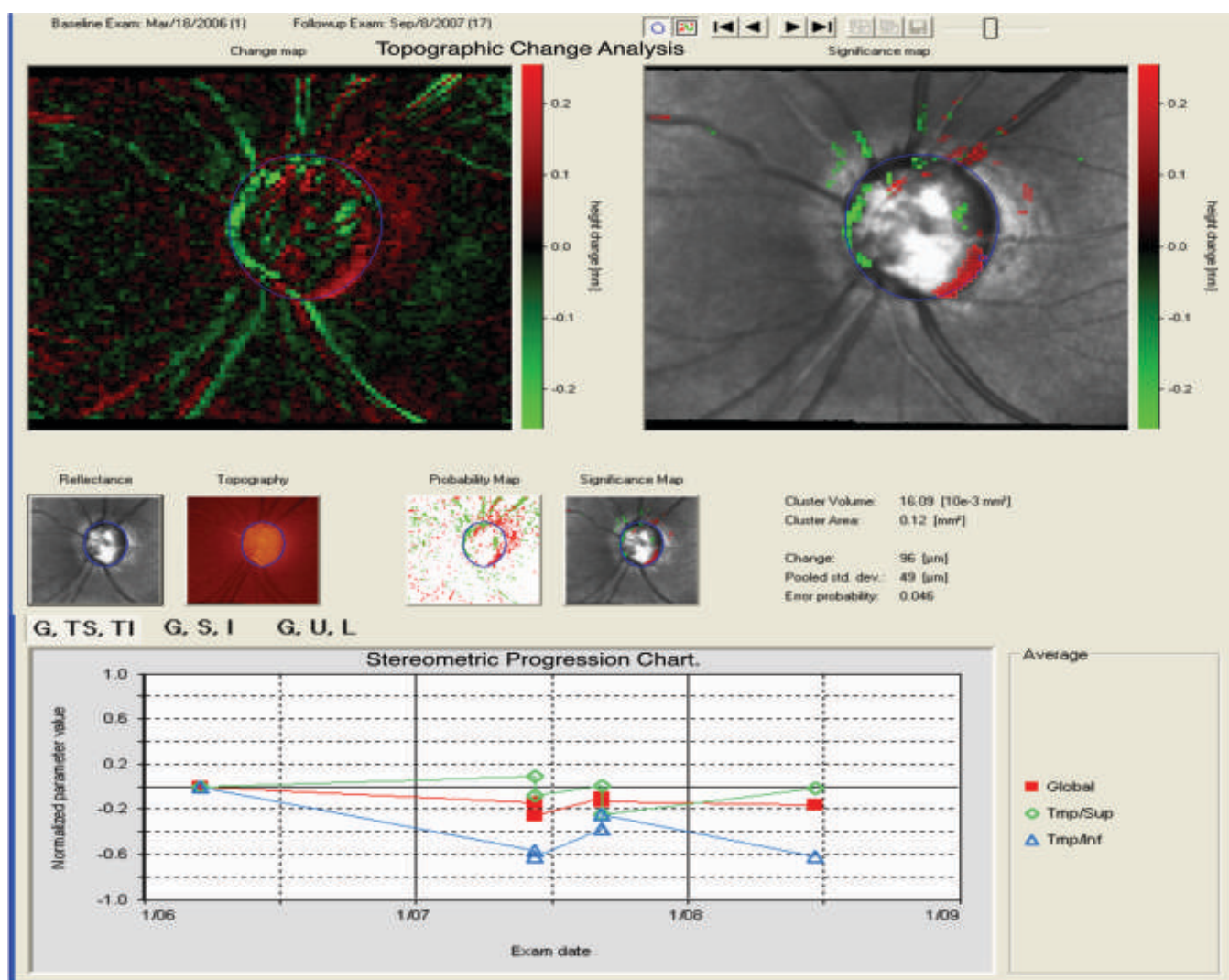


Fig. 6. Showing the Topographic change analysis and Stereometric Progression Chart.





**Case 2.** A sixty year elderly lady (Fig. 11, 12, 13, &14) presented with a visual acuity of 6/9 in RE and 6/9 in LE. She was using prostaglandins once a day in both eyes. IOP was BE 14 mmHg. Gonioscopy showed open angles in both eyes. Central corneal thickness was RE 519  $\mu\text{m}$  and LE 517  $\mu\text{m}$ . The optic disc size was RE 1.72mm<sup>2</sup> and LE 2.09mm<sup>2</sup>. Optic disc RE was obliquely oval with inferior extension of the cup with loss of inferior rim. The RNFL showed significant loss inferiorly. There was narrowing of the inferior temporal retinal arteriole with increased inferior tessellation. Optic disc in LE was horizontally oval with inferior loss of neuroretinal rim and generalised retinal nerve fiber layer thinning inferiorly. LE also showed narrowing of the inferior temporal retinal arteriole with increased inferior tessellation. Automated perimetry showed the presence of superior arcuate and nasal loss in RE and nasal loss in LE. The contour lines show significantly reduced height for the inferior poles in both eyes indicating a loss of retinal nerve fiber layer thickness. The bilateral report shows a comparison of parameters between the right and left eye.

Qualitative evaluation of the optic disc remains a very important and reliable expertise in the diagnosis and management of glaucoma. However it is important that subjective and qualitative clinical expertise is supported by objective measurements. This is relevance of the HRT. HRT measurements are reproducible and have small values of between 25 to 49  $\mu\text{m}$  SD for relative height values and 0.04 to 0.06 mm<sup>2</sup> for rim or cup area. Several studies have evaluated the utility of CLSO for diagnosis in glaucoma. The sensitivity of HRT as a diagnostic tool has varied from 74 to 92 and of specificity from 81 to 97 in different studies. These are in agreement to that of an expert observer assessing the optic disc on stereoscopic photographs. While abnormal results on HRT suggest structural damage, they should always be considered in association with a patients history and the established methods of clinical assessment of the glaucoma subject. Never in isolation. It is not a substitute but an associate of clinical evaluation. The segmentation of the optic disc in sectors may enable one

**Table of Values. for Case 1.**

Parameters (OD)	Global	Parameters (OS)	Global
disc area [mm <sup>2</sup> ]	2.28	disc area [mm <sup>2</sup> ]	1.88
cup area [mm <sup>2</sup> ]	0.49	cup area [mm <sup>2</sup> ]	1.13
rim area [mm <sup>2</sup> ]	1.79	rim area [mm <sup>2</sup> ]	0.75
cup/disc area ration	0.21	cup/disc area ration	0.6
cup volume [mm <sup>3</sup> ]	0.07	cup volume [mm <sup>3</sup> ]	0.37
mean RNFL thickness [mm]	0.26	mean RNFL thickness [mm]	0.11
RNFL cross sectional area [mm <sup>2</sup> ]	1.4	RNFL cross sectional area [mm <sup>2</sup> ]	0.55
linear cup/disc ration	0.46	linear cup/disc ration	0.77

**Table of Values for Case 2.**

parameters (OD)	global	parameters (OS)	global
disc area [mm <sup>2</sup> ]	1.72	disc area [mm <sup>2</sup> ]	2.09
cup area [mm <sup>2</sup> ]	1.12	cup area [mm <sup>2</sup> ]	1.38
rim area [mm <sup>2</sup> ]	0.6	rim area [mm <sup>2</sup> ]	0.71
cup/disc area ration [.]	0.65	cup/disc area ration [.]	0.66
cup volume [mm <sup>3</sup> ]	0.47	cup volume [mm <sup>3</sup> ]	0.51
mean RNFL thickness [mm]	0.09	mean RNFL thickness [mm]	0.15
RNFL cross sectional area [mm <sup>2</sup> ]	0.41	RNFL cross sectional area [mm <sup>2</sup> ]	0.79
linear cup/disc ration [.]	0.81	linear cup/disc ration [.]	0.81

## Clinical Implication and Conclusions:

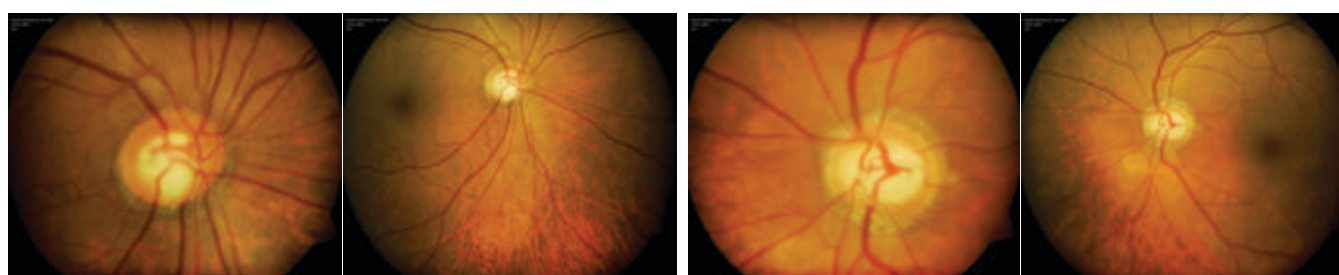


Fig. 11. RE Optic Disc of Case 2.

Fig.12 LE Optic Disc of Case 2

to further identify patterns of glaucoma damage evolution in terms of loss of neuroretinal rim and retinal nerve fiber layer. This may indicate modalities to preempt significant loss in areas of greater visual potential. Objective measurements may help us identify and define parameters that constitute normal, suspicious and abnormal and help in the classification of glaucomatous damage. This has implications in standardisation of research and clinical findings.

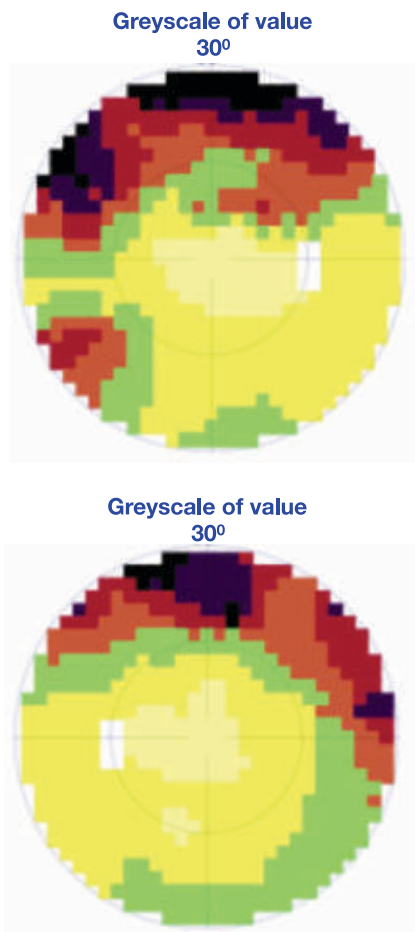


Fig.13. Case. 2. Automated perimetry- grey scale.  
RE Mean defect 3.9dbs. and LE mean defect

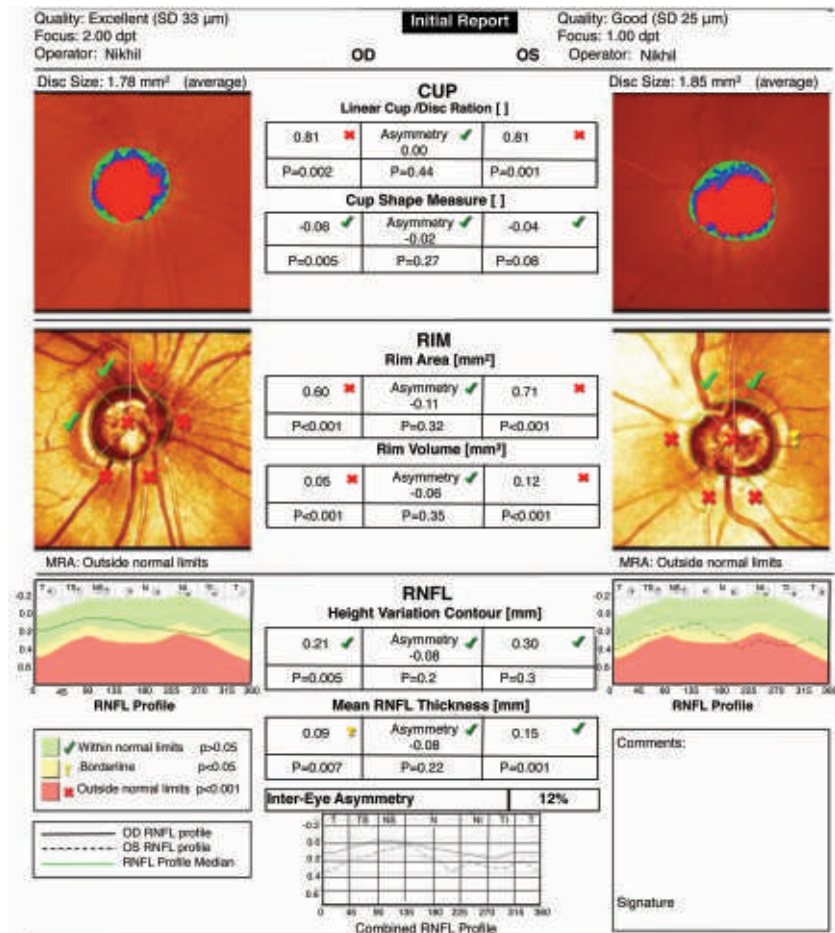


Fig. 14. Showing bilateral print out of HRT with information about optic disc morphometric parameters and inter eye comparisons of Case 2.

## References

1. The Essential HRT Primer. Editors: Murray Fingeret, John G. Flanagan, Jeffrey M. Liebman. Jocoto Advertising Inc. San Ramon 94583. 2005. by Heidelberg Engineering.
2. Atlas of Laser Scanning Ophthalmoscopy. A.F. Scheuerle, E. Schmidt. Springer Verlag. Berlin Heidelberg 2004.
3. Glaucoma Module. Heidelberg Retina Tomograph. Operating Instructions. Software Version 3.0. Heidelberg Engineering GmbH.
4. Wollstein G, Garway-Heath DF, Hitchings RA: Identification of early glaucoma cases with scanning laser ophthalmoscope. Ophthalmology 1998; 105:1557-1563.



# SCANNING LASER POLARIMETRY

## Introduction:

Glaucoma is a progressive optic neuropathy characterized by pathological loss of retinal ganglion cells and their axons, the Retinal Nerve Fiber Layer (RNFL) with or without associated visual field loss. The loss of Retinal ganglion cells in glaucoma is irreversible; therefore early detection of its presence and progression is critical to management of glaucoma. Although standard automated achromatic perimetry (SAP) has been the most commonly used method to assess presence and progression of glaucoma, several studies have shown that deterioration of the optic nerve head (ONH) and retinal nerve fiber layer (RNFL) often precede the visual field loss detected by perimetry by a number of years. Besides perimetry is subjective method of evaluation and depends on various parameters. Structural analysis with an imaging device that provides objective measures has been recommended by various international guidelines to be included in the standard exam of all glaucoma practices<sup>1</sup>. Scanning Laser Polarimetry (SLP) is one of the objective tests that provide quantitative analysis of the retinal nerve fiber layer (RNFL) thickness using confocal polarimetric scanning laser ophthalmoscope. It is also fast and easy to use<sup>2,3</sup>.

## Principle:

SLP uses polarized laser light to measure the retinal nerve fiber layer's thickness (RNFL). RNFL is a highly ordered array of parallel axon bundles that contain microtubules, which contribute to the birefringence. SLP with a variable corneal compensator (GDxVCC) provides an accurate and reproducible measurement of the RNFL thickness, based on the principle that polarized light passing through the birefringent neuronal microtubules (RNFL) undergoes a measurable phase shift, known as retardation, which is linearly related to histologically measured RNFL tissue thickness alteration (Retardation) it produces in the polarization of light passing through it. The retardation measured is converted into a measure of the retinal nerve fiber layer thickness based upon the assumption that there is a linear relation between the thickness and optical properties of this layer. SLP collects and analyzes data points in the 15° field around the optic nerve. It identifies the 1,500 thickest data points in the superior and inferior quadrants and the 1,500 median data points in the nasal and temporal quadrants. From these data points, it performs its calculations. The software of GDx compares an individual patient's results against a normative database for analysis against patients of the same age, sex and race. The database's age range is 18 to 80 years. If a patient is outside this age range, you won't have statistical norms to compare against, but you'll still get information about the RNFL.

The available models of the GDx are as under: GDx VCC, GDx ECC, GDx pro. The GDxPRO is current evolution in GDx technology that is backward compatible with the last generation of GDx.

## Indications:

1. Early and moderate glaucomatous damage for identification of damage as well as for follow ups to see the progression of the disease.
2. Advance cases: Limited role, but can be of help when perimetry may not be possible.
3. Preperimetric Glaucoma: It helps in identifying loss before it is seen on visual field<sup>5</sup>; This is very useful in ocular hypertensive patients.
4. Glaucoma suspects: Patients with suspicious looking disc, large disc large cup. In a clinical setting, especially GDx may be helpful for identifying glaucoma suspect patients at risk of developing glaucomatous visual field loss. Further scanning laser polarimetry using the GDx VCC has been found to be an important tool in defining the management strategies of glaucoma suspects<sup>6</sup>.

5. Progression analysis: This provides rates of structural change in glaucoma patients. Literature review suggests that the scanning laser polarimetry (SLP) provides quantifiable and reproducible measurements of the optic disc and peripapillary retinal nerve fiber layer (RNFL). Rates of change as quantified by the RNFL thickness is related to glaucoma progression as detected by conventional methods<sup>7,8</sup> (eg, visual fields and optic disc photography).
6. It is also useful in monitoring neurological patients.

### How to interpret:

The GDx VCC report contains number of images:

**1. Patient's Identification Data:** The name and the birthdate of the patient are especially important. Correct age of the patient allows for an appropriate comparison of patients with the normative database incorporated in the machine.

**2. Disc Dimensions:** The objective assessment helps in comparison with the normal disc size, inter-eye symmetry and identification of any abnormality.

**3. Image quality score:** An image quality score of equal to or greater than 8 is necessary to get a good final image report.

**4. The reflectivity (fundus) image:** It allows checking for image quality. It allows an assessment of how well centered the annulus is on the optic disc. Colored intensity map (greater reflectance corresponds to a lighter color). The higher reflectivity usually suggests good RNFL thickness.

**5. The retardation (RNFL thickness) image:** The retardation image also known as thickness map displays RNFL thickness in a color-coded format. A heat map of RNFL thickness, with hotter colors representing greater retardation values (and, therefore, thicker RNFL).

Thick RNFL values- yellow, orange, red, Thin RNFL values - dark blue, light blue, and green

**True Wedge defects:** Two criteria define a true RNFL defect. First, the defect must extend back to the optic nerve usually superotemporal or inferotemporal in location and second, it must be at least as large as an arteriole. Remember, too, that not all NFL defects represent glaucoma. Some artifacts in the fundus are pseudo- defects; also, 7% of normal patients will have NFL defects.

**6. The statistical deviation image:** The statistical deviation image highlights pixels in which retardation values fall below those in the normative database. The color of the pixel indicates the level of probability of deviation from normal, with the probability values displayed in the central panel. This reveals location and magnitude of RNFL defects over the entire thickness map.

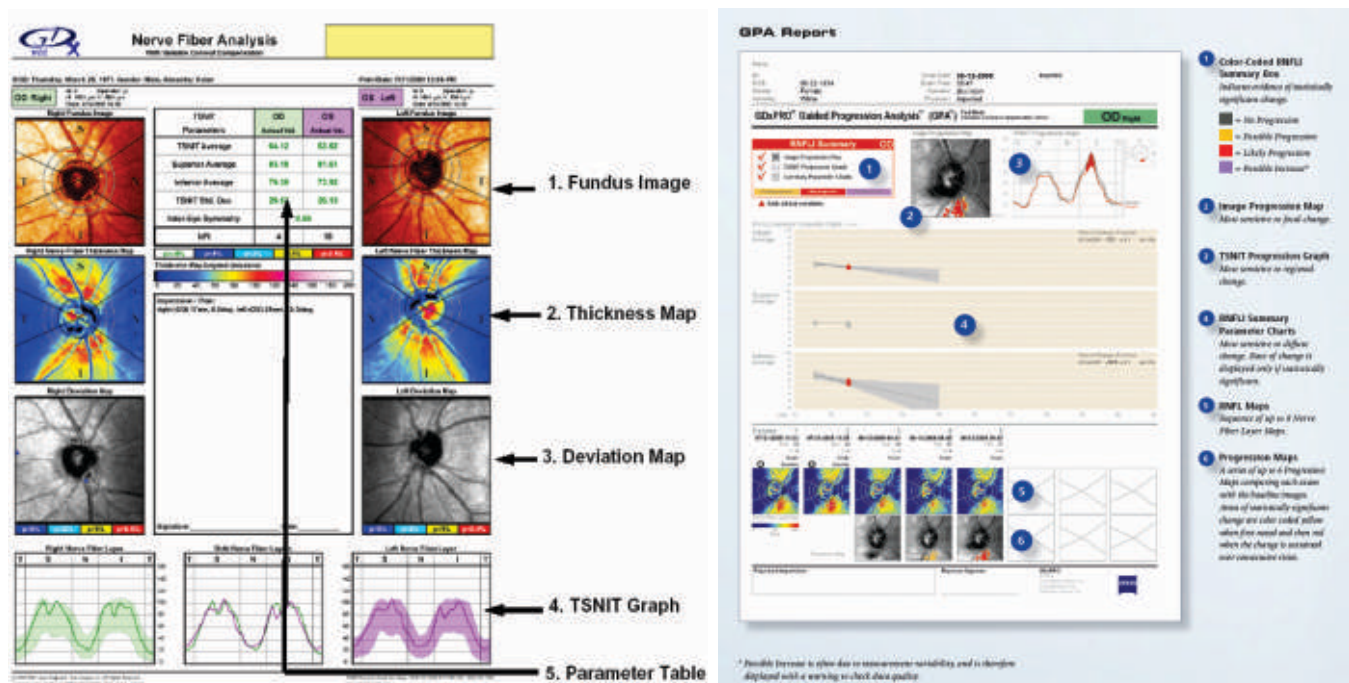
**7. Temporal-Superior-Nasal-Inferior-Temporal (TSNIT) graphs: (RNFL profile plots).** The TSNIT graphs (RNFL profile plots) display the RNFL thickness values around the measurement annulus in relation to the statistically normal range. The center panel allows an appreciation of the symmetry between the 2 eyes.

**8. Parameter Table:** The TSNIT parameters are summary measures based on RNFL thickness values within the calculation circle. These parameters are automatically compared to the normative database and are quantified in terms of likelihood of normality. Three average values are calculated:

- TSNIT Average refers to the average RNFL thickness around the entire calculation circle.
- Superior Average refers to the average RNFL thickness in the superior 120° region of the calculation circle.

- Inferior Average refers to the average RNFL thickness in the inferior 120° region of the calculation circle.
- Normal parameter values - green letters in white box
- Abnormal values - color-coded based on their probability of normality
- Normal eyes - good symmetry, values around 0.9.

**9. The Nerve Fiber Indicator (NFI):** NFI is a global measure based on the entire RNFL thickness map is calculated using a support vector machine algorithm based on several RNFL measures. The cut-offs suggested by the manufacturer are 0 to 30 for within statistically normal limits, 31 to 50 for borderline and 51 to 100 for outside statistically normal limits. NFI is a single number, ranging from 0 to 100, indicates the likelihood of glaucoma existing in the patient at the present time. It doesn't tell whether glaucoma is advanced or progressive, simply whether it's present. The closer to 0, the more likely the patient is normal; the closer to 100, the more likely he has glaucoma.



## Sensitivity:

1. In a study to compare the sensitivity and specificity of retinal nerve fiber layer thickness (RNFLT) measurements made using RTVue-100 Fourier-domain optical coherence tomography (RTVue-OCT) and scanning laser polarimetry with variable (GDx-VCC) or enhanced compensation (GDx-ECC), it was found that all methods were similarly highly specific, but for localized RNFLT damage RTVue-OCT was statistically and clinically significantly more sensitive than GDx-VCC and GDx-ECC. However most of the cases detected with glaucoma were identified with all 3 methods<sup>9</sup>.
2. In another trial the Diagnostic accuracy of SD-OCT and GDxVCC were compared using typical scans (TSS=100). It was found that decreasing TSS is associated with a decrease in diagnostic accuracy for discriminating healthy and glaucomatous eyes by scanning laser polarimetry. NFI was less influenced than the global or sector retinal nerve fiber layer thickness. Most importantly, the TSS score should be included in the standard printout<sup>10</sup>.

3. Some trials have also been conducted to evaluate the sensitivities for dissimilar disc sizes. It was concluded that sensitivities were not significantly different for the GDx VCC ( $P=0.928$ ). Logistic marginal regression also showed that sensitivity of GDx was independent of the disc size. However the sensitivity increased with increasing disease severity (decreasing mean deviation).<sup>11,12</sup>

### Progression:

1. Longitudinal progression in NFI obtained with GDxVCC was significantly correlated for 3-5 years with that in HFA parameters, such as Mean Deviation and Pattern Standard Deviation<sup>13</sup>.
2. Various studies have shown that the GDx VCC is able to detect longitudinal change in the RNFL of eyes with progressive disease detected by conventional methods optic disc stereo photographs and/or visual fields<sup>14</sup>.
3. Some authors investigated the impact of retardance pattern variability on retinal nerve fiber layer (RNFL) measurements over time using SLP with variable (GDx VCC) and enhanced corneal compensation (GDx ECC). Glaucoma suspect and glaucomatous eyes with 4 years of follow-up participating in the Advanced Imaging in Glaucoma Study were prospectively enrolled<sup>4</sup>.
4. An Observational cohort study was done in 431 eyes of glaucoma and glaucoma suspect, 34 eyes (8%) showed progression by SAP and/or optic disc stereo photographs. The GDx-GPA detected 17 of these eyes for a sensitivity of 50%. Fourteen eyes showed progression only by the GDx-GPA with specificity of 96%. Positive and negative LR were 12.5 and 0.5, respectively<sup>15</sup>.
5. Atypical Retardation Patterns had a significant effect on detection of progressive RNFL loss with the GDx VCC. Eyes with large amounts of atypical patterns, great fluctuations on these patterns over time, or both may show changes in measurements that can appear falsely as glaucomatous progression or can mask true changes in the RNFL<sup>16</sup>.
6. There is an agreement for detecting progression with the GDx Guided Progression Analysis, automated Perimetry and optic disc photography<sup>17</sup>.

### Limitations:

1. Does not measure actual RNFL thickness (inferred value).
2. Measures RNFL at different locations for each patient.
3. Does not differentiate true biological changes from variability.
4. Limited use in moderate/advanced glaucoma.
5. Requires a wider data base from the Indian population.
6. Young children database not available.
7. Difficult in nystagmus very small pupil and media opacities like cataract, corneal pathology, vitreous opacities etc.
8. Affected by anterior and posterior segment pathology like:
  - Ocular surface disorders
  - Macular pathology - Disruption of the Henle's layer by macular disease can result in failure of the strategies for neutralization of corneal birefringence required for accurate SLP with VCC.
  - Cataract and refractive surgery
  - Refractive errors (false positive in myopia)



- Peripapillary atrophy (scleral birefringence with RNFL measurement)
  - ? High IOP may influence
9. Atypical Retardation Patterns had a significant effect on detection of progressive RNFL loss with the GDx VCC. Eyes with large amounts of atypical patterns, great fluctuations on these patterns over time, or both may show changes in measurements that can appear falsely as glaucoma progression.
  10. Lack of histological validation of Scanning Laser Polarimetry (SLP)
  11. Backward compatibility: Recent versions of GDx are not compatible with previous versions, making it difficult to track long-term progression in patients while upgrading to the latest technology.

### Case -1:

A 51 year old male (routine check up) diagnosed to have suspicious looking optic disc. Systemic history: Hypertension, Diabetes mellitus. No family history of glaucoma. No past ocular systemic history. BCVA : OD: 6/6 (-3.0 Dsph) , OS: 6/6P (-3.0 DDsph). IOP(Applanation) : OD: 17 mmHg, OS: 12 mmHg. Pachymetry: OD: 505  $\mu$ m , OS: 510  $\mu$ m. Both eyes Slit lamp examination – normal . Gonioscopy showed angles wide open visible up to scleral spur. OU Fundus – Normal. Optic nerve: RE – C/D 0.6 deep cup with inferior notch, RNFL wedge defect at inferior pole. LE- Normal C/D - 0.4, healthy neuroretinal rim. Visual field 30-2 SITA STD: RE – Superior altitudinal scotoma. LE showed field changes in superior arcuate region, not matching the disc changes. GDx VCC – showed RE as well a LE inferotemporal wedge defect on retardation map as well as deviation map. RE changes were more than LE . Diurnal variation for intraocular pressure was carried out, which ranged between 15-19 in right eye and 13-20 in left eye.

Discussion: This case present to us with dilemma of having normal tension glaucoma in right eye which is having typical glaucomatous disc changes and corresponding visual field changes and left eye normal as IOP and disc changes. The diurnal variation was not showing high spike. The question arises that in left eye which has normal looking optic disc and IOP. But the visual field changes in superior hemisphere is not matching the clinical impression. GDx VCC showed positive changes in both eyes. GDx VCC confirms the structural damage. This asked for more vigorous investigations and management. Disc photography was done which also showed a small wedge in left eye. Patient was then asked to stop antihypertensive medication for 2 days and repeat

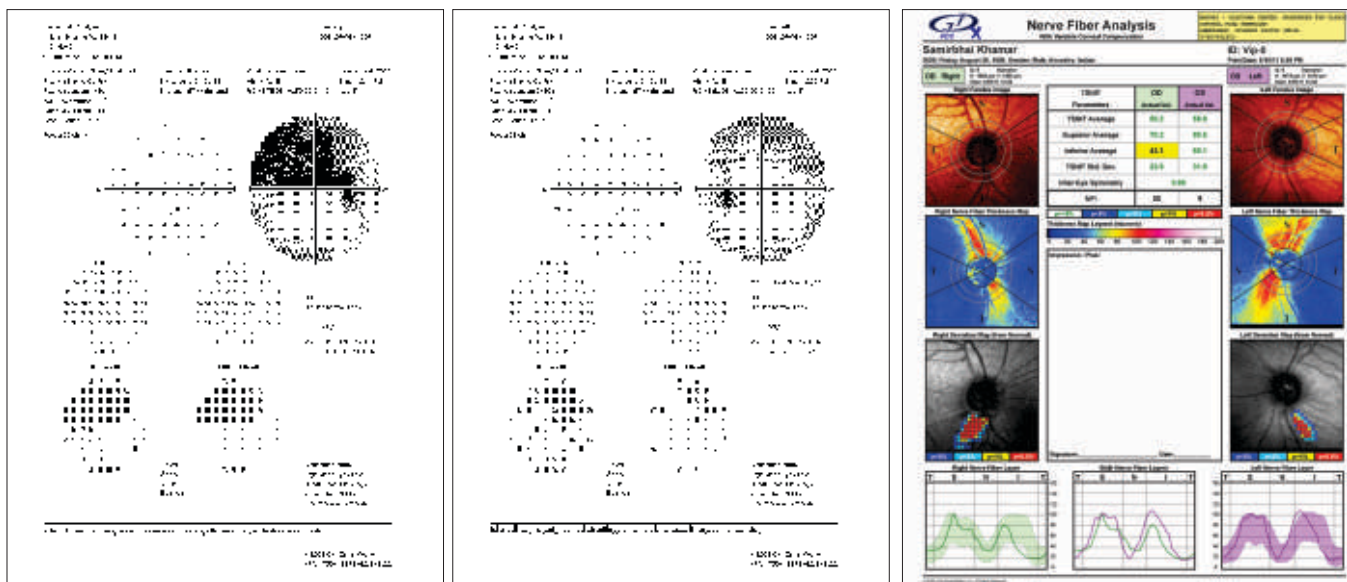
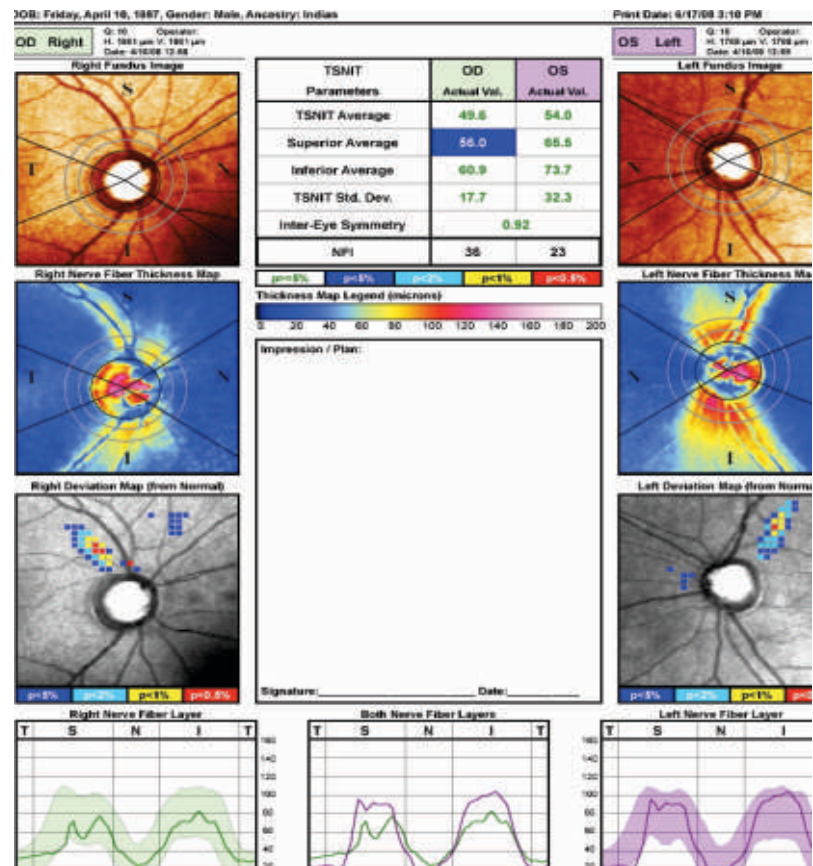
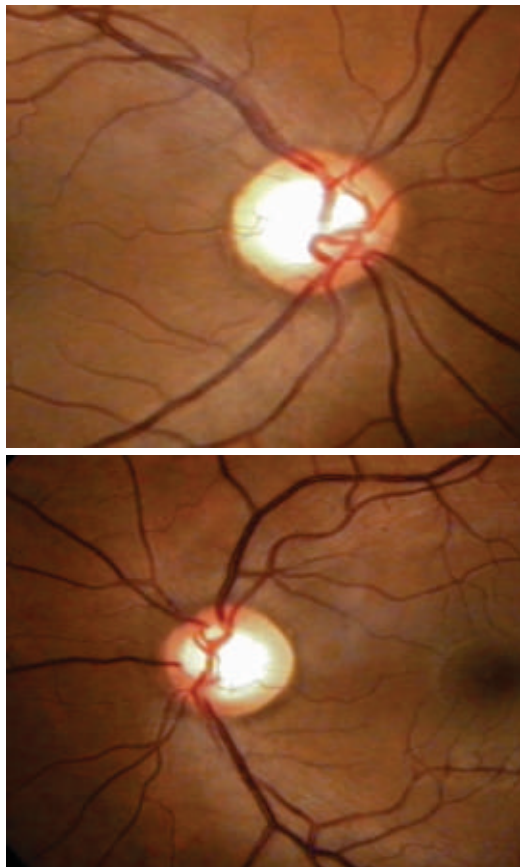
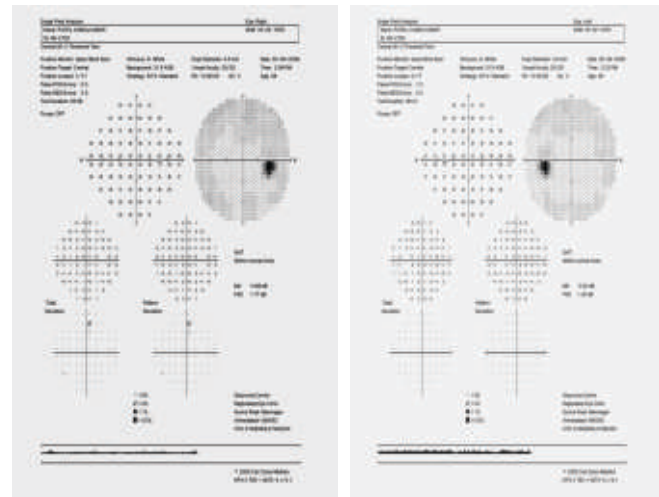


Fig : RE visual field, LE visual field, GDxVCC:

diurnal variation showed early morning spike RE- 24, and LE – 27 mm of Hg. So both eyes diagnosis of POAG is made. Scanning laser polarimetry GDx is a subjective, reproducible test. It detects structural damage (RNFL loss) earlier than functional test. It not only adds to the clinical judgment but also guides us for management. This test to be included as a routine in all cases of ocular hypertension, early to moderate glaucoma, large disc large cup or suspicious looking optic nerve not only for diagnosis but also for monitoring the disease.

## Case -2

39 year male was diagnosed to have an ocular hypertension before 4 years based on normal visual field examination and disc evaluation using slit lamp biomicroscopy. His IOP on Applanation was - RE - 24 mm Hg, LE - 25 mm Hg respectively. Pachymetry -RE - 548 micron , LE - 540 micron. Fundus – BE – C/D 0.7 with healthy NRR . Gonioscopy – BE - Open angles grade 3. SLE – NAD .BCVA RE : 6/6 -8.5 Sph / -1.5 Cyl @ 20 , LE : 6/6 -6.0 Sph / -1.75 Cyl @ 160 GDx VCC was normal in both eyes. Visual field - SAP – 30-2 normal in BE. GDx VCC – BE – normal , repeated every year. Visual fields repeated every year and found to be stable. In absence of field defects and other risk factors, he was kept under observation with frequent monitoring for 3 years follow ups.



At 4 years of follow up, the GDx VCC evaluation revealed superotemporal defects in both eyes. The GDx revealed progression while visual fields were still normal....medical therapy for raised IOP was initiated using PG analogue lowering IOP to 17 in RE and 15 in LE respectively. The case represents the ability of GDx VCC to detect changes objectively before they are detected using field evaluation and disc evaluation and secondly to detect progression of disease before other parameters.

### Summary:

Retinal Nerve Fiber Layer measurements obtained with the GDx have been found to be highly reproducible in a long-term situation, supporting the use of this instrument for longitudinal assessment of the RNFL. It is also a useful adjunct for the early diagnosis of glaucoma cases. The GDx VCC scanning laser polarimeter is able to identify longitudinal RNFL loss in eyes that showed progression in optic disc stereo photographs and/or visual fields. These findings suggest that this technology could be useful to detect and monitor progressive disease in patients with an established diagnosis of glaucoma or suspected of having the disease. Its application in the management of advanced cases of glaucoma remains limited. Caution should be exercised when using the GDx VCC for longitudinal evaluation of the RNFL in eyes with atypical retardation patterns. A word of caution when using the GDx VCC in screening for glaucoma. The results should not be used in isolation, but in conjunction with conventional methods of optic disc and visual field assessment.

### References

1. 1st Global AIGS Consensus Meeting on "Structure and Function in the Management of Glaucoma", San Diego, November 2003.
2. Vizzeri G, Kjaergaard SM, Rao HL, Zangwill LM. Role of imaging in glaucoma diagnosis and follow-up. *Indian J Ophthalmol.* 2011 Jan;59 Suppl:S59-68.
3. Lemij HG, Reus NJ. New developments in scanning laser polarimetry for glaucoma. *Curr Opin Ophthalmol.* 2008 Mar;19(2):136-40.
4. Grewal DS, Sehi M, Cook RJ, Greenfield DS; Advanced Imaging in Glaucoma Study Group. The impact of retardance pattern variability on nerve fiber layer measurements over time using GDx with variable and enhanced corneal compensation. *Invest Ophthalmol Vis Sci.* 2011 Jun 23;52(7):4516-24.
5. Kim HG, Heo H, Park SW. Comparison of scanning laser polarimetry and optical coherence tomography in preperimetric glaucoma. *Optom Vis Sci.* 2011 Jan;88(1):124-9.
6. Shaikh A, Salmon JF. The role of scanning laser polarimetry using the GDx variable corneal compensator in the management of glaucoma suspects. *Br J Ophthalmol.* 2006 Dec;90(12):1454-7.
7. G P Heeg, N M Jansonius. The Groningen Longitudinal Glaucoma Study III. The Predictive Value of Frequency-Doubling Perimetry and GDx Nerve Fibre Analyser Test Results for the Development of Glaucomatous Visual Field Loss. *Eye* : (2009) 23, 1647–1652
8. Mansouri K, Leite MT, Medeiros FA, Leung CK, Weinreb RN. Assessment of rates of structural change in glaucoma using imaging technologies. *Eye (Lond).* 2011 Mar;25(3):269-77.
9. Garas A, Vargha P, Holló G. Comparison of diagnostic accuracy of the RTVue Fourier-domain OCT and the GDx-VCC/ECC polarimeter to detect glaucoma. *Eur J Ophthalmol.* 2012 Jan;22(1):43-52. doi: 10.5301/ejo.5000011.
10. Hoesl LM, Tornow RP, Schrems WA, Horn FK, Mardin CY, Kruse FE, Juenemann AG, Laemmer R. Glaucoma Diagnostic Performance of GDxVCC and Spectralis OCT on Eyes With Atypical Retardation Pattern. *J Glaucoma.* 2011 Oct 24.
11. Garudadri CS, Rao HL, Parikh RS, Jonnadula GB, Selvaraj P, Nutheti R, Thomas R. Effect of Optic Disc Size and Disease Severity on the Diagnostic Capability of Glaucoma Imaging Technologies in an Indian Population. *J Glaucoma.* 2011 Apr 25.
12. Oddone F, Centofanti M, Tanga L, Parravano M, Michelessi M, Schiavone M, Villani CM, Fogagnolo P, Manni G. Influence of disc size on optic nerve head versus retinal nerve fiber layer assessment for diagnosing glaucoma. *Ophthalmology.* 2011 Jul;118(7):1340-7.
13. Makabe K, Takei K, Oshika T. Longitudinal relationship between retinal nerve fiber layer thickness parameters assessed by scanning laser polarimetry (GDxVCC) and visual field in glaucoma. *Graefes Arch Clin Exp Ophthalmol.* 2011 Oct 6.
14. Vermeer KA, Lo B, Zhou Q, Vos FM, Vossepoel AM, Lemij HG. Event-based progression detection strategies using scanning laser polarimetry images of the human retina. *Comput Biol Med.* 2011 Sep;41(9):857-64.
15. Luciana M. Alencar, MD1,2, Linda M. Zangwill, PhD1, Robert N. Weinreb, MD1, Christopher Bowd, PhD1, Gianmarco Vizzeri, MD1, Pamela A. Sample, PhD1, Remo Susanna Jr, MD2, and Felipe A. Medeiros, MD, PhD1,2. Agreement for Detecting Glaucoma Progression with the GDx Guided Progression Analysis, Automated Perimetry and Optic Disc Photography. *Ophthalmology.* 2010 March ; 117(3): 462–470.
16. Felipe A. Medeiros, Luciana M Alencar, Linda . Impact of Atypical Retardation Patterns on Detection of Glaucoma Progression using the GDx with Variable Corneal Compensation . *Am J Ophthalmol.* 2009 July ; 148(1): 155–63.
17. Felipe A. Medeiros, Luciana M. Alencar, Linda M. Zangwill, Christopher Bowd, Gianmarco Vizzeri, Pamela A. Sample, and Robert N. Weinreb. Detection of Progressive Retinal Nerve Fiber Layer Loss in Glaucoma Using Scanning Laser Polarimetry with Variable Corneal Compensation. *Invest Ophthalmol Vis Sci.* 2009 April ; 50(4): 1675–1681. doi:10.1167/iovs.08-2712.



# OPTICAL COHERENCE TOMOGRAPHY

Glaucoma is an optic neuropathy with characteristic optic nerve appearance and visual field loss for which elevated intraocular pressure (IOP) is one of the main risk factors<sup>1</sup>. This characteristic optic nerve appearance results from structural glaucomatous changes which usually precede functional deterioration (visual field loss). Worldwide, glaucoma is the most common cause of irreversible blindness and the second leading cause of blindness<sup>2</sup>. The optic disc and the RNFL are the principal sites of apparent glaucomatous damage which precedes glaucomatous visual field alterations. In 60% of reported cases, RNFL defects preceded detection of visual field defects by approximately 6 years<sup>3</sup>. Accurate early detection and monitoring of ONH and RNFL defects has become the prime focus of effective management of glaucoma.

## INTRODUCTION

Optical coherence tomography (OCT) is an imaging technology that employs low-coherence interferometry to obtain cross-sectional images of the ocular tissues. The principle of OCT is analogous to that of ultrasonography, but uses light instead of sound to acquire high resolution images of the ocular structures. A beam of light is shone on the eye and reflections returning from the structures are analysed to produce realtime images.

## PRINCIPLES OF OCT

A light source is directed to a partially reflecting mirror that splits the light into two beams: one is directed towards a mirror placed at a known distance (reference mirror) and the other is directed towards the eye, from where it will reflect back. The back-reflected light from the eye is combined with the back-reflected light from the reference mirror and coherent light is compared. Interference is produced when two light pulses coincide. The reference mirror is then moved so that the time delay of the reference light pulse can change accordingly and therefore other intraocular structures can be measured. The laser beam is passed throughout the tissue and a series of scans are obtained to produce a two-dimensional map.

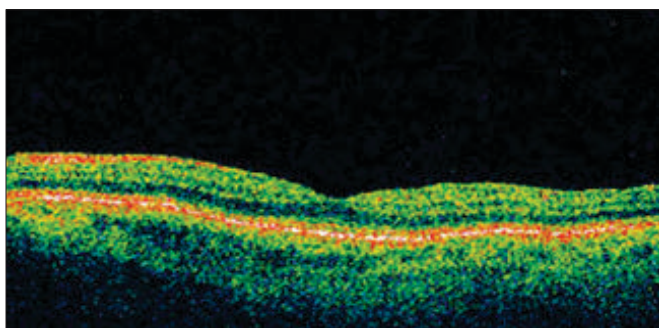
## POSTERIOR SEGMENT-OCT

Posterior segment OCT uses light of 830nm to obtain images of the posterior segment structures such as optic nerve head (ONH), retinal nerve fibre layer and macula. It has software that facilitates image acquisition, storage, retrieval and analysis. Several topographic ONH parameters are automatically calculated and are reported along with a colour-coded map and ONH topographic map.

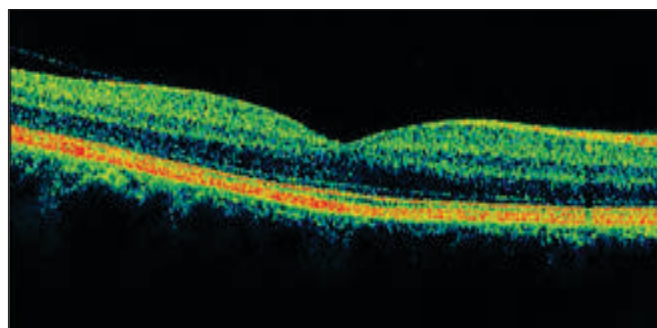
OCT has evolved through different modifications from OCT1 to Fourier domain/Spectral domain OCT. The newer method of spectral-domain (SD) OCT has higher speed and resolution than its predecessor, Stratus OCT. Spectral-domain OCT also captures 3-dimensional images of optic disc and surrounding tissue components. Three of the commonly used SD-OCT devices are the Spectralis (Heidelberg Engineering, Dossenheim, Germany), the Cirrus (Carl Zeiss Meditec, Dublin, CA), and the RTVue (Optovue Inc., Fremont, CA).

Axial resolution of Spectral-domain (SD) OCT is twice higher (5–7 microns) than Stratus OCT (approximately 10 microns). The SD OCT instruments can acquire B-scans 45 to 130 times faster than Stratus OCT and multiple B-scans can be acquired at the same location, when averaged results in a speckle-noise-reduced image with clearly distinguishable boundaries between retinal layers. It also has 3-dimensional (3-D) eye-tracking system (Spectralis HRA\_OCT; Heidelberg Engineering, Heidelberg, Germany) that reduces motion induced artifacts.





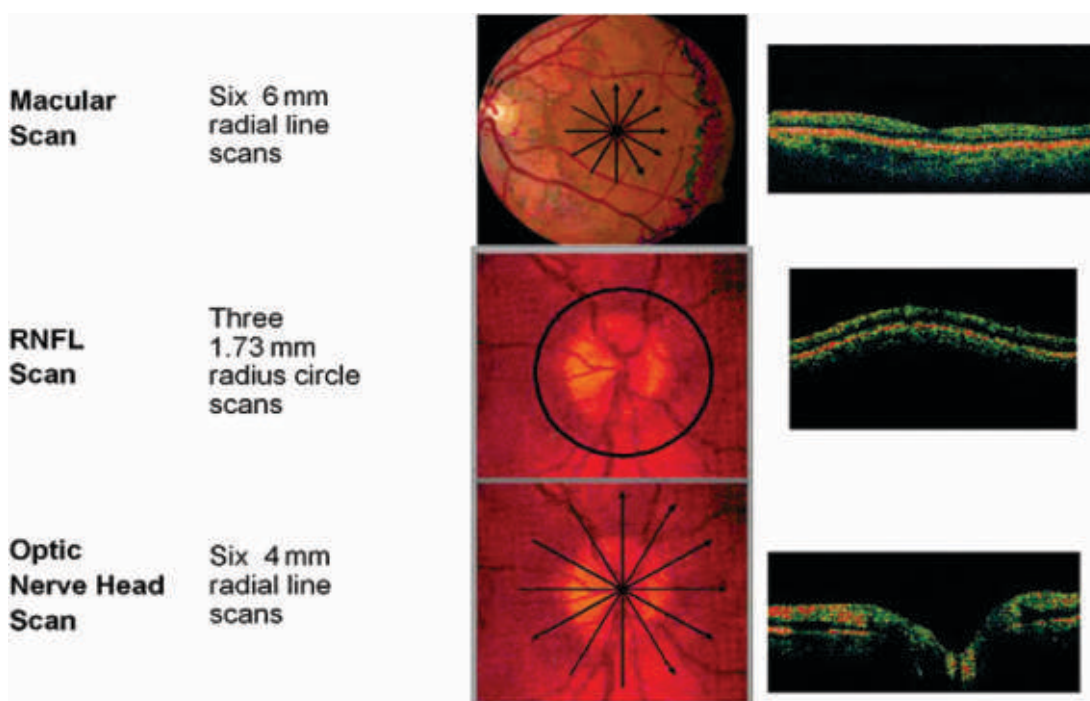
Stratus OCT



Spectral Domain OCT

Fig 1: showing higher resolution and clearer delineation of retinal layers with Spectral OCT.

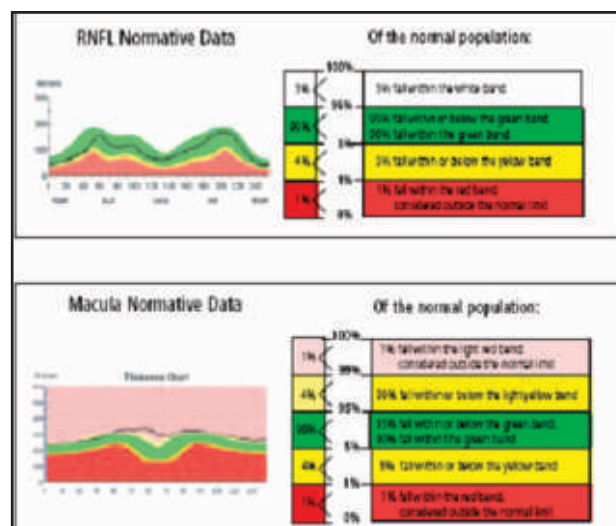
## SCANNING PROTOCOLS:



## INTERPRETATION OF OCT:

### QUALITY ASSESSMENT:

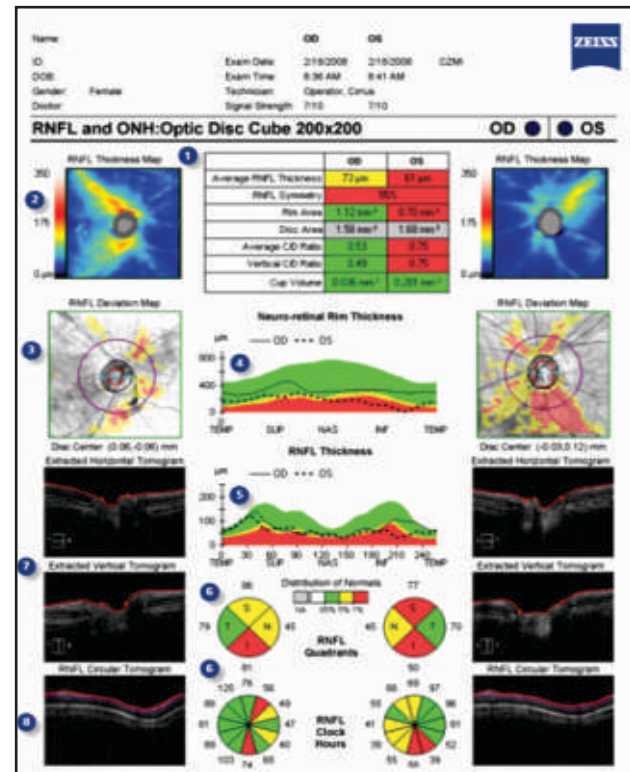
1. Appropriate centration of the peripapillary circular scan is essential for accurate measurements of RNFL thickness.
2. Signal strength value of the scan should be greater than 5.
3. Homogeneity of the RNFL scan is important since loss of reflectivity can affect the overall quality.



The below figure shows normative data of Stop-Light color scheme scan with areas of defect in any given patient (normative population). This helps the physician to easily read the chart without much difficulty.

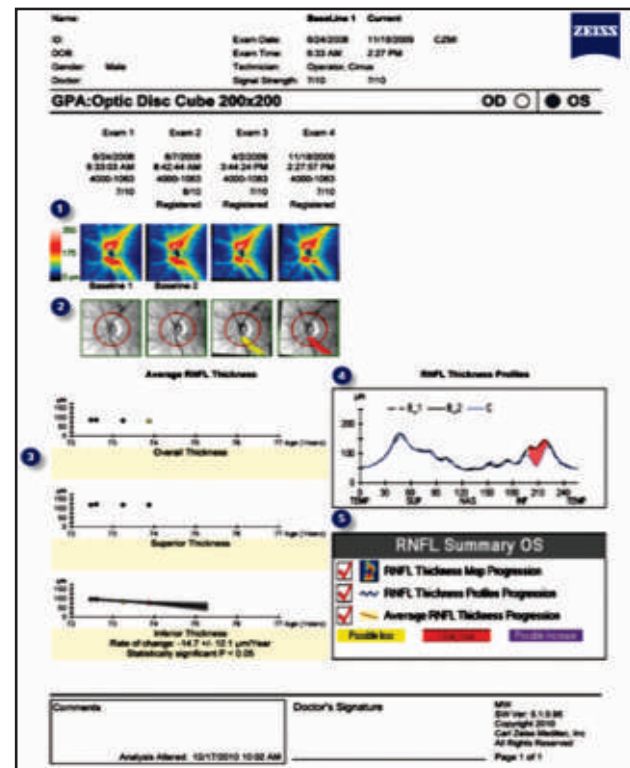
#### CIRRUS OCT RNFL AND ONH ANALYSIS REPORT

1. Key Parameters, compared to normative data are displayed in a table format.
2. RNFL thickness map is a topographical display of RNFL.
3. RNFL deviation map Shows deviation from normal.
4. Neuro retinal Rim Thickness profile is matched to normative data.
5. RNFL TSNIT graph displays patient's RNFL measurement compared to normative data.
6. RNFL Quadrant and clock hour average thickness is matched to normative data.
7. Horizontal and Vertical B scan are extracted from the data cube. RPE layer and disc boundaries are shown in black. ILM and cup boundaries are shown in red.
8. RNFL Calculation circle shows boundaries of the RNFL layer segmentation.



#### CIRRUS OCT GLAUCOMA PROGRESSION ANALYSIS REPORT

1. RNFL Thickness maps – Provide a topographical display of RNFL for each exam.
2. RNFL Thickness Change maps – demonstrate change in RNFL between exams. Up to 6 progression maps are compared to baseline. Areas of statistically significant change are color-coded yellow when first noted and then red when the change is sustained over consecutive visits.
3. Average RNFL Thickness – values are plotted for each exam. Yellow marker denotes change from both baseline exams. Red marker denotes change sustained over consecutive visits.
4. RNFL Thickness profiles – TSNIT values from exams are plotted. Areas of statistically significant change are color-coded yellow when it is first noted and red when the change is sustained over consecutive visits.
5. RNFL Summary – summarizes Guided Progression Analysis and indicates with a check mark if there is possible or likely loss of RNFL.



**OCT MACULAR ANALYSIS REPORT:** OCT scans of the macula involve a strategy of six intersecting lines that intersect at the foveal center. Assessment of the macular region in glaucoma is necessary because over 50% of retinal ganglion cells lie in the macular region and hence it is the ideal region to detect early cell loss.

In Macular thickness analysis by Stratus OCT central 3 mm of the posterior pole have the highest scan density compared with the outer (3 mm to 6 mm) concentric ring.

### GANGLION CELL COMPLEX

The Ganglion Cell Complex(GCC) which includes 1) the retinal nerve fiber layer (NFL) 2) the ganglion cell layer (GCL) and 3) the inner-plexiform layer (IPL) becomes thinner due to ganglion cell loss in glaucoma. Spectral OCT(RTVue) measures the thickness of GCC in macular region and gives analysis compared to an extensive normative database.

GCC scan data is displayed as thickness map of GCC layer. This map is colour-coded where thicker regions are displayed in hot colours (yellow and orange) and thinner regions in cooler colours (blue and green). GCC map for a normal eye shows a bright circular band surrounding the macula representing thick GCC as depicted below.

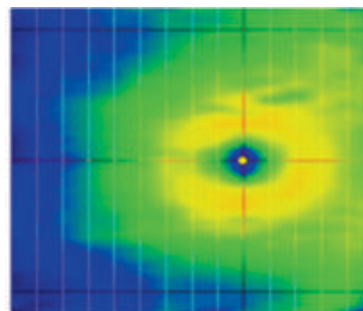


Fig 2. Normal macular GCC

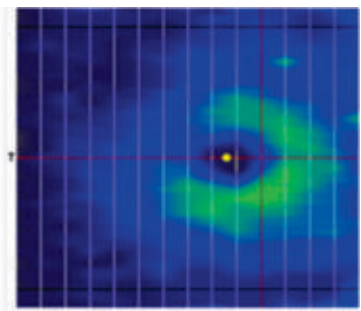


Fig 3. Thinned macular GCC

### **CASE REPORTS:**

**CASE 1:** A male patient aged 27years was referred for glaucoma evaluation due to suspicious optic disc.

On evaluation BCVA – 6/6 , SLE-WNL , Gonioscopy-open angles in both eyes

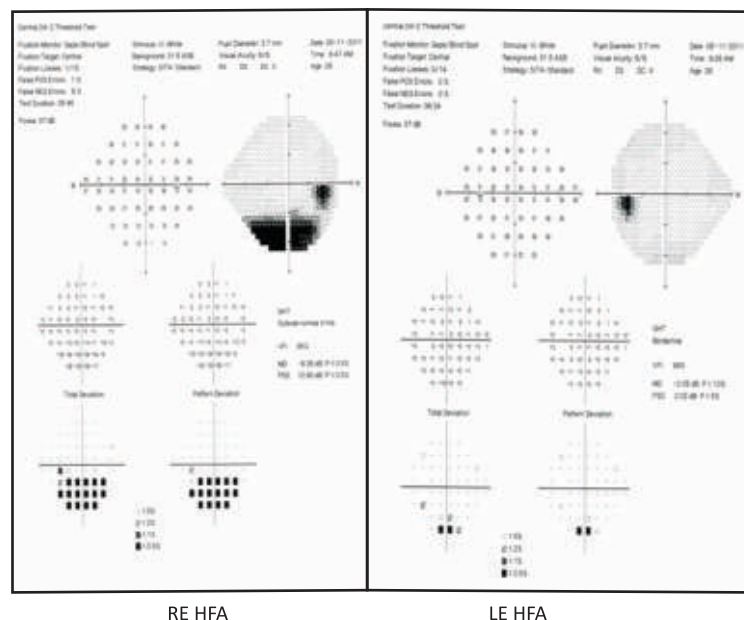
IOP measured by applanation tonometry - 14mmHg (BE)

24hr Diurnal variation showed a variation of 4mmHg in RE and 3mmHg in LE

It was followed by Fundus photography, OCT and HFA which are as depicted below.

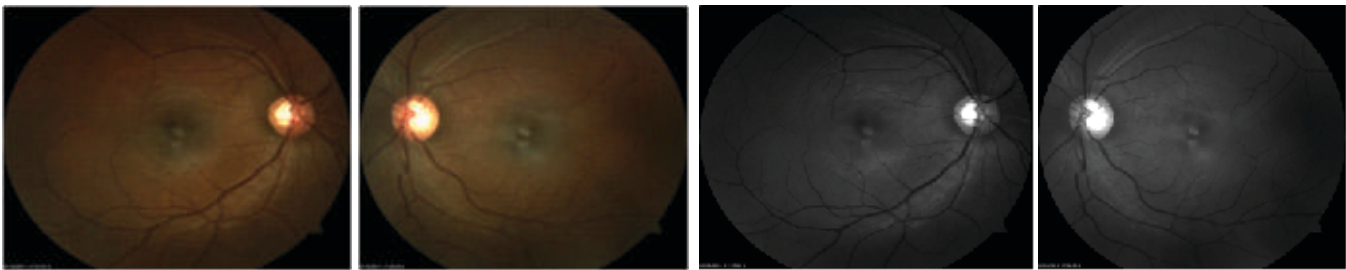
Superior NRR thinning and RNFL loss was evident on photograph in BE. But OCT showed gross RNFL loss in RE and decrease in superior average with mild superior thinning in LE quantitatively.

HFA showed corresponding visual field defect in RE and normal field in LE.

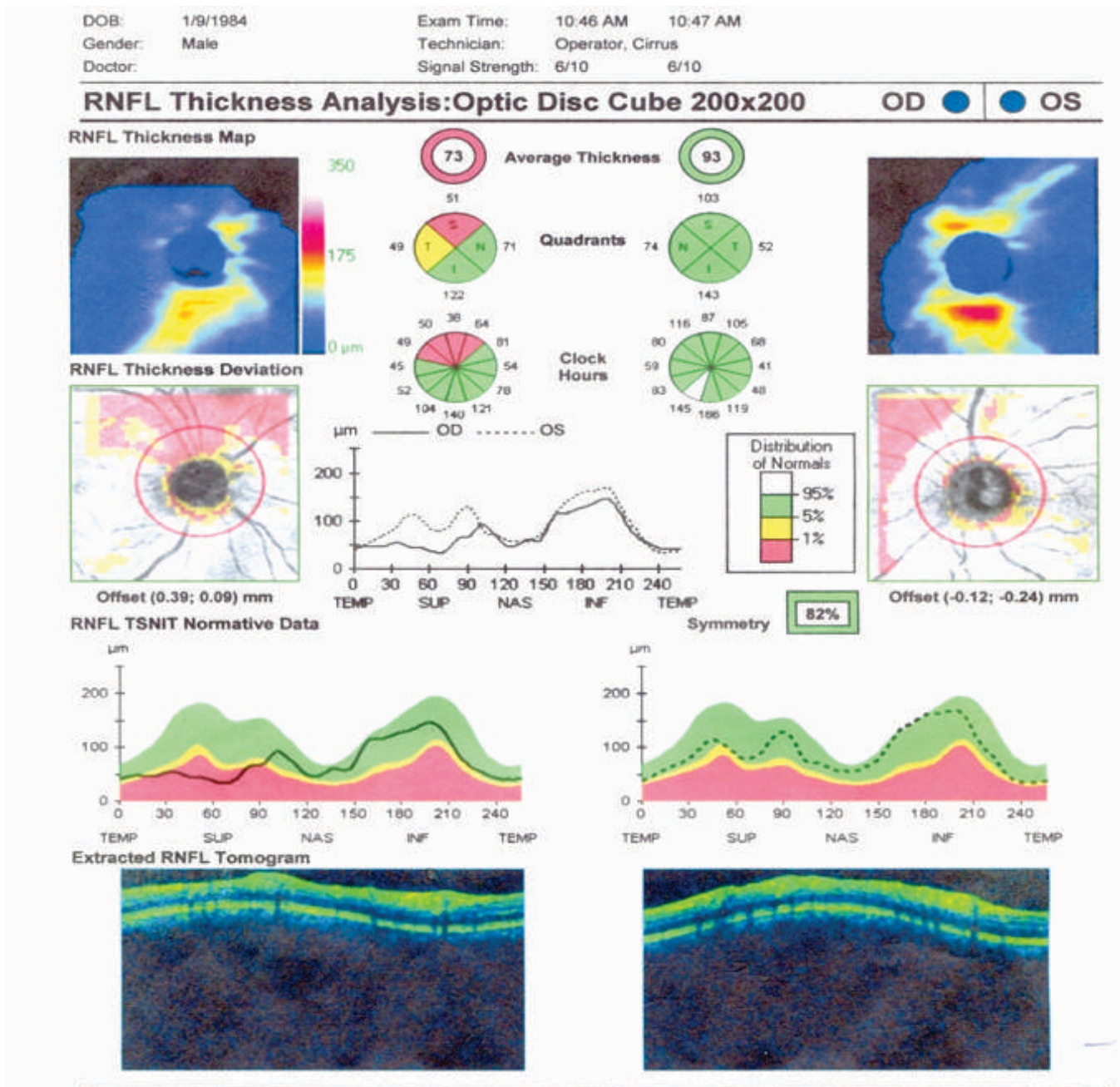


OCT supplements the clinical findings and may have an edge over the other investigative modalities in some patients(preperimetric glaucoma) in quantifying the loss.





## OCT RNFL Analysis



## OCT RNFL Analysis




**CASE 2:** An young male patient aged 23 years diagnosed with secondary open angle glaucoma (steroid induced) was referred for surgical management.

On evaluation: UCVA-6/6, SLE- Vernal conjunctivitis, Gonioscopy – open angles in BE.

IOP measured by applanation tonometry was 10mmhg in BE. (Patient was on Timolol 0.5% bid)

HFA, Fundus photos and OCT is as depicted below.



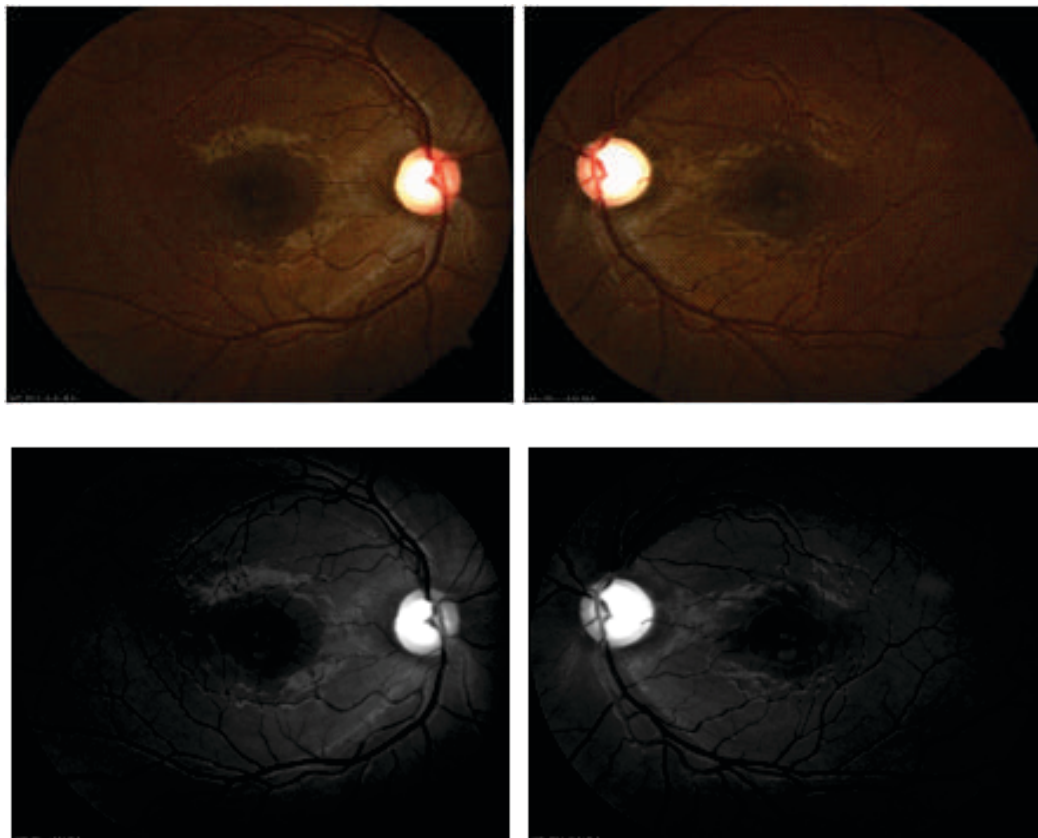
RE- showed CDR 0.7 with thinning of superior NRR and RNFL loss in the superior quadrant which was confirmed on fundus photo. OCT showed RNFL loss in the superior, inferior and temporal quadrants on RNFL thickness map with corresponding blunting of the double hump pattern on TSNIT graph.

HFA showed paracentral defect in the inferior arcuate region.

LE- CDR 0.8 with thinning of superior and inferior NRR, and corresponding RNFL defect was confirmed on fundus photo. OCT showed total loss of RNFL in superior, temporal and inferior quadrants with borderline thinning in the nasal quadrant- on the RNFL thickness map with flattening of the curve on TSNIT graph.

HFA shows dense inferior arcuate scotoma with sparing of the superior hemifield.

In this case it is evident that OCT quantified a greater damage preceding visual field loss.





### CLINICAL APPLICATIONS OF OCT

1. Retinal nerve fiber layer analysis

RNFL thickness measurement is graphed in a TSNIT orientation and compared to age matched normative data. Decreased RNFL thickness represents glaucoma.

2. ONH analysis

Disc margins are objectively identified by using signal from and of RPE. Key parameters include cup to disc ratio and horizontal integrated rim volume

3. Macular thickness analysis

Thinning of macula may reflect glaucomatous loss.

4. A recent software upgrade of Stratus OCT (Stratus OCT Version 5.0) has included the Glaucoma Progression Analysis to evaluate the association between average RNFL thickness and age.

### ADVANTAGES OF OCT

1. Easy to operate.
2. It has the best resolution among all the imaging devices.
3. Has a rapid image acquisition time.
4. Being a non-contact technique, images can be obtained without causing undue discomfort to the patient.
5. Qualitative and quantitative data can be collected and analysed in an objective and reproducible way.
6. It is the only technology capable of imaging the optic nerve head, retinal nerve fibre layer and macula.
7. Can obtain posterior segment images without pupillary dilatation.

### PRECISION OF OCT IN EARLY DIAGNOSIS OF GLAUCOMA

Various studies on OCT<sup>4-8</sup> have shown:

- Measurement of RNFL thickness with OCT has been reliable in discriminating normal from glaucomatous eyes.
- OCT has good sensitivity and specificity for differentiating normal from glaucomatous eyes. A study by Chang et al showed stratus OCT sensitivity and specificity for average RNFL abnormal at the 5% level were 80% and 94% respectively and at 1% level were 61% and 100% respectively. Cirrus OCT sensitivity and specificity for average RNFL abnormal at the 5% level were 83% and 88% respectively and at the 1% level were 65% and 100% respectively.

### LIMITATIONS OF OCT

1. Automatic demarcation of the optic disc borders by the machine may be inaccurate in cases of parapapillary atrophy, which would confound the interpretation of optic disc topography. This may limit the ability of OCT to detect the progression of glaucomatous optic disc damage.
2. It is possible that localised NRR/ optic cup changes would be missed by the interpolation algorithm.



3. Depends on the skill of the operator.
4. Poor quality of images in dense media opacities.
5. Difficult in unco-operative patients.
6. Expensive instrumentation.

## CONCLUSION

Medicine and technology are advancing hand in hand to provide quality health care. Technology innovation and improvement will continue to impact health services.

OCT is a new technology. Any new technology introduces both difficulties and opportunities. The lack of large scale normative database is perhaps the greatest issue in interpretation of OCT results at this point of time. These issues must be resolved before OCT can be accepted for widespread clinical use in glaucoma. Apart from this note of caution the potential utility of OCT as a glaucoma diagnostic tool is extremely high as,adequate data exist to evaluate the patients in conjunction with other clinical parameters. A patient can be followed over time, using his or her own baseline. The two eyes of the patient can be compared for asymmetry, and a single eye can be examined for focal or sectoral NFL thinning.

All pieces of the glaucoma puzzle must be put together in order to care appropriately for the patient. The clinician must correlate clinically with IOP, ONH and NFL appearance, visual field data, as well as quantitative data contributed by technology, to detect glaucoma and its progression.

## References

1. Rand AR. Shield's Textbook of Glaucoma. 6<sup>th</sup>Edn. Lippincott: Williams and Wilkins; 2011.p.77-78.
2. Robert LS, Mark FL, Michael VD. Becker-Shaffer's Diagnosis and Therapy of the Glaucomas.8<sup>th</sup>Edn. Mosby: Elsevier; 2009.p.175-181
3. Sommer A, Katz J, Quigley HA et al. Clinically detectable nerve layer atrophy precedes the onset of glaucomatous field loss. Arch Ophthalmol. 1991;109: 77-83..
4. Tarek MS, Mark BS, Roger AH, Jonathan GC. Glaucoma-Medical diagnosis and Therapy. Vol.1. Saunders: Elsevier; 2009.p.232-35.
5. Schuman JS, Hee MR, FuliakitoCA,etal.Quantification of nerve fibre layer thickness in normal and glaucomatous eyes using Optical Coherence Tomography. Arch Ophthalmol.1995; 113:586-96.
6. Leung CK, Cheung CY Weinreb RN, et al. RNFL imaging with Spectral-Domain OCT- A variability and diagnostic performance study. Ophthalmology.2009;116:1257-63.
7. Leung CK, Chan WM, Yung WH, et al. Comparison of macular and peripapillary measurements for the detection of glaucoma: an OCT study. Ophthalmology. 2005;112:391-400.
8. Parikh RS, Parikh S, Sekhar GC, et al. Diagnostic capability of OCT( Stratus OCT 3) in early glaucoma. Ophthalmology. 2007;114:2238-43.
9. Chang RT et al. Sensitivity and specificity of Time-domain versus Spectral-domain OCT in diagnosing early to moderate glaucoma. Ophthalmology. 2009;116:2294-99.

# ULTRASOUND BIOMICROSCOPY AND ANTERIOR SEGMENT OCT

Ultrasound biomicroscopy (UBM) is a high frequency ultrasound (35-50 MHz) used to image the anterior segment (Fig 1). Its main utility is to image in eyes with opaque cornea, under the iris (ciliary body region), visualize the trabeculotomy fistula and provide an objective quantification of the angle parameters. It also aids in surgical planning for both the cornea and glaucoma surgeon in eyes with post keratoplasty glaucoma.<sup>1-3</sup>

UBM has its limitations related to being a contact investigation and pressure from the eye cup used during the procedure can distort the angle.

- **Examination of the anterior chamber angle:**

UBM, can be used to examine the angle structures as iris, ciliary body, and scleral spur can be recognized easily. The scleral spur is the only constant landmark allowing one to interpret images and is the key for analyzing angle pathology. The exact quantification of the angle measurement can be done in degrees and the angle opening distance and recess area can also be documented.

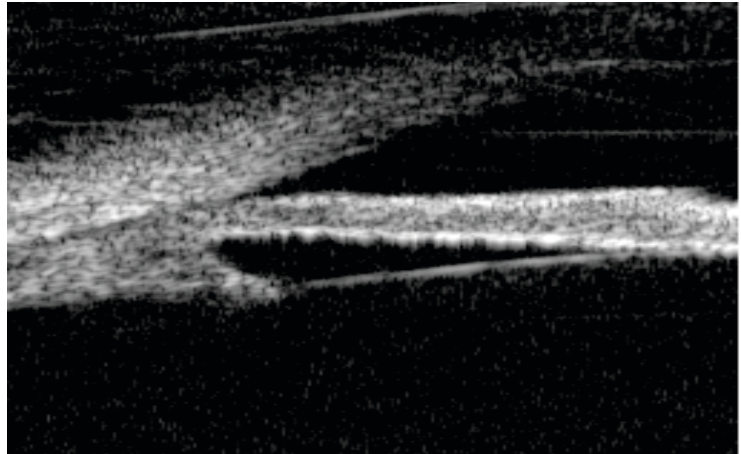


Fig 1 UBM image of the angle and ciliary body

- **Biometry of the Anterior Segment**

The UBM can be used to determine the corneal thickness, anterior chamber depth, posterior chamber depth, IOL thickness, iris thickness, ciliary body thickness, scleral thickness etc. Sulcus to sulcus and angle to angle measurements can also be performed with a 35 MHz probe.

- **Determining the mechanism of primary glaucoma**

Ultrasound biomicroscopy is usually able to determine the mechanism of elevated intraocular pressure (angle closure versus open angle) by showing the relationship between the peripheral iris and trabecular meshwork.

In addition, imaging of the anterior segment structures is possible even in eyes with corneal edema or corneal opacification that precludes gonioscopic assessment. UBM is an important tool as it can identify the spontaneous occlusion of the angle in

decreased illumination in dark room provocative testing. This helps to identify “at risk” population which can then be subjected to a laser iridotomy.

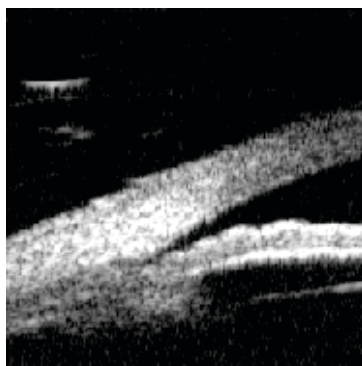

Figure 2 : Open angle in bright illumination

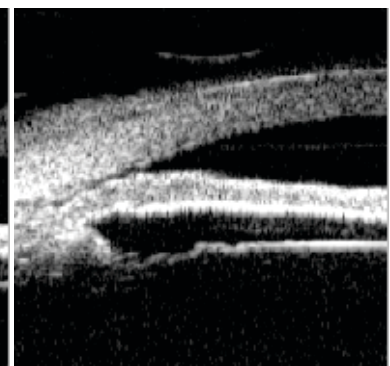


Figure 3 : Irido-corneal apposition in dark

In plateau iris syndrome, UBM reveals an irido-trabecular contact with a broad anteriorly displaced ciliary body, absent ciliary sulcus and steep anterior angulation of the peripheral iris. (Fig.4)

In eyes with peripheral anterior synechiae, UBM can reveal the extent of iridocorneal adhesions (Figure 5), even if the cornea is hazy or opaque.

#### • Post Traumatic Glaucoma

After blunt ocular trauma, UBM can be used to evaluate iris-angle abnormalities including angle recession, iridodialysis and cyclodialysis. (Figure 6,7) Angle recession is characterized on UBM by a posterior displacement of the point of attachment of the iris to the sclera, a widening of the ciliary body face with no disruption of the interface between the sclera and ciliary body.

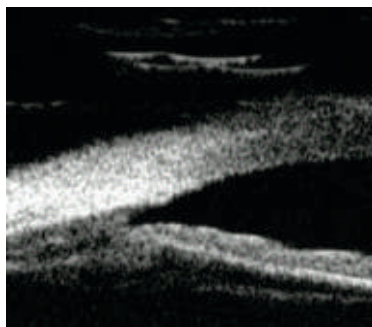


Fig: 6 Angle recession

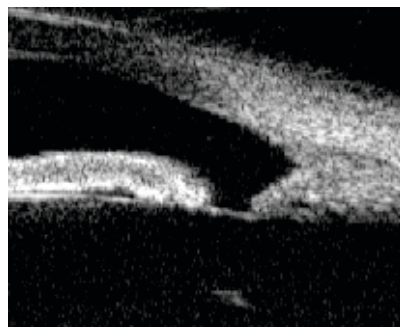


Fig: 7 Iridodialysis

#### • Secondary Glaucoma

The UBM can diagnose various types of lens induced glaucomas such as Phacomorphic glaucoma and glaucoma due to anterior subluxation of lens. It is helpful to know the circumference of intact zonules and the extent of zonular dialysis in pseudoexfoliation syndrome. In case of IOL induced glaucoma, it can clearly delineate the position of the optic and haptic and is especially helpful in pseudophakic bullous keratopathy cases to determine the cause for glaucoma. (Figure: 8)

#### Evaluation of cysts and tumors causing angle closure

This technology can be used to determine the internal character of a lesion (solid or cystic Figure 9,10), to ascertain whether the lesion involves the anterior ciliary body or is restricted to the iris, and to measure the full extent of the lesion. UBM can reveal whether the lesion involves only partial thickness or full thickness of the stroma and can thereby aid in surgical planning. It allows measurement of the lesion's thickness and determination of the presence or absence of intraocular invasion. With the UBM one can follow up the progression or regression of the tumor.

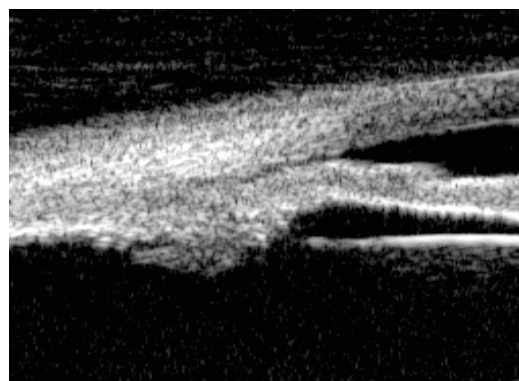


Fig: 4 Plateau Iris

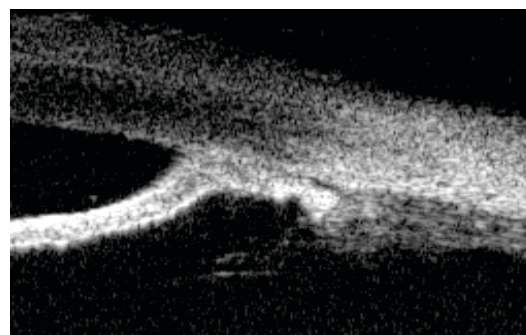


Fig 5: Peripheral anterior synechiae

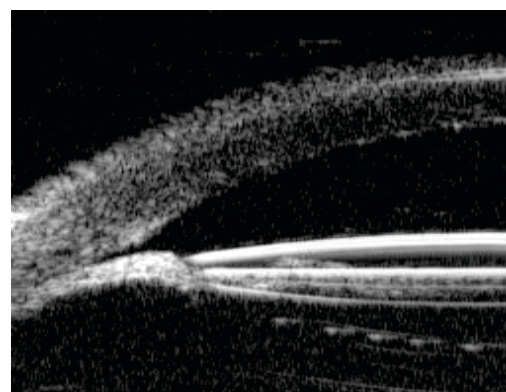


Fig: 8 PBK with Secondary Angle Closure by ACIOL



- **Determining functional status of a filtering surgery**

After trabeculectomy, UBM can demonstrate the patency of sclerostomy aperture and peripheral iridectomy and whether the filtering bleb is flat, shallow, or deep. It helps to determine the site of obstruction and cause for trabeculectomy failure ( Figure: 11)

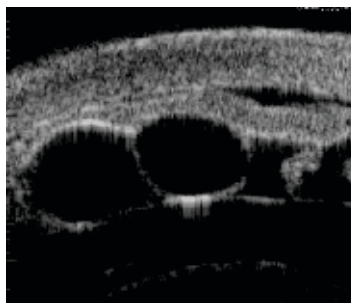


Fig: 9 Iris cysts

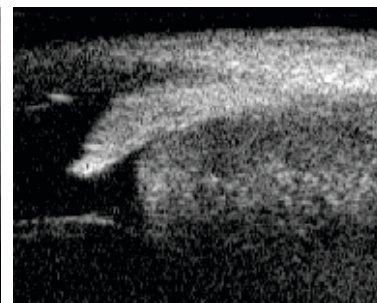


Fig: 10 Ciliary Body tumor

## Anterior Segment Optical Coherence Tomography

Optical coherence tomography (OCT) is a cross-sectional, three-dimensional, high-resolution imaging modality that uses low coherence interferometry to achieve axial resolution in the range of 3-20  $\mu\text{m}$ . OCT is similar to ultrasound except that light (1310 nm) is used instead of sound. It is a completely noninvasive technique. OCT at 1.3 $\mu\text{m}$  wavelength of light is better suited for anterior segment imaging as the amount of scattering in tissue is lower at this wavelength, which enables increased penetration and better visualization. Additionally 1.3 $\mu\text{m}$  wavelength is strongly absorbed by water in ocular media and therefore, only 10 % of the light incident on the cornea reaches the retina, preventing any retinal photo toxicity. The scanning speed is 4000 axial scans per image, giving an image acquisition rate of 8 frames per second. With standard software, the lateral resolution of ASOCT is 60  $\mu\text{m}$  and the axial resolution is 18  $\mu\text{m}$  compared to 50  $\mu\text{m}$  and 25 $\mu\text{m}$  respectively by UBM. With high-resolution corneal software, axial resolution of ASOCT can reach 8 - 10 $\mu\text{m}$ .

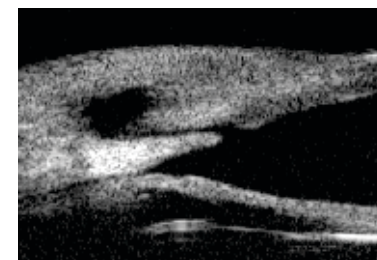


Figure 11 Patent Trabeculectomy fistula

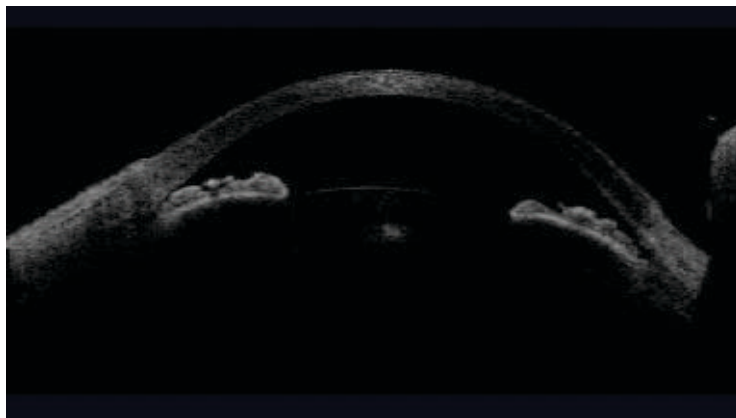


Figure 12. AS-OCT image showing chronic PACG with closed angles.

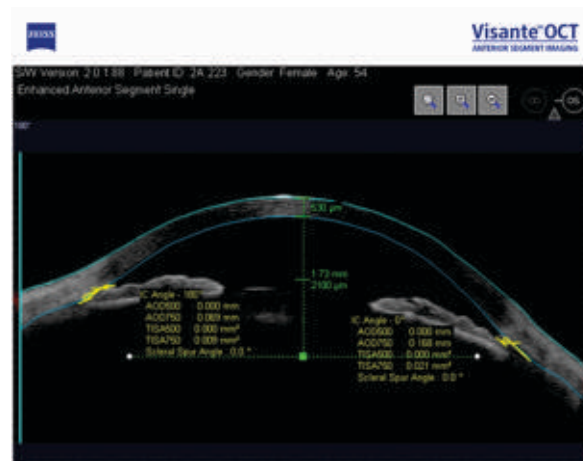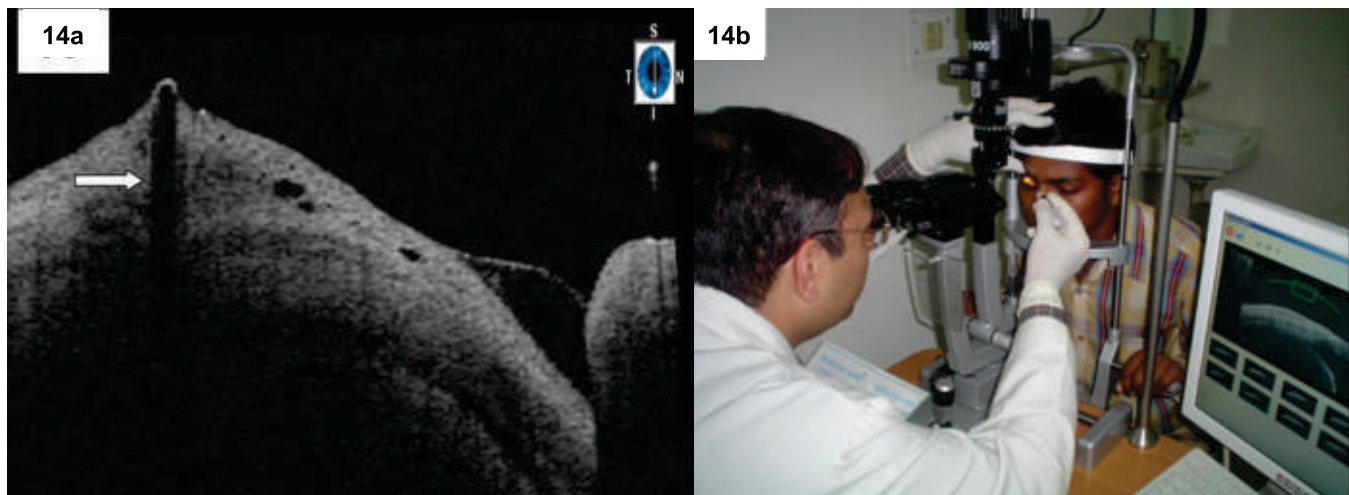


Figure 13. Quantitative assessment of the angle using the AS-OCT

The main utility of ASOCT is non contact imaging of the angle, especially useful in screening for angle closure and objective documentation of the angle structures and biometry (figure 12-14). The major distinction in imaging of ASOCT vs UBM, is that imaging posterior to the iris is not possible with the ASOCT. Hence the ciliary body is not visualized on ASOCT scans. Rest of the applications are similar to the ones outlined for UBM.<sup>4-6</sup>

## ASOCT guided intervention

There is a special type of ASOCT attached to the slit lamp (SLOCT), which can be used for ASOCT guided surgical interventions.<sup>7</sup>



SL-OCT guided needling for restoration of bleb function can be performed. (Figure 14). This technique allowed visualization of the internal bleb architecture, which is often not visible on routine slit lamp evaluation in eyes with a vascularised fibrotic bleb or under a thick tenon's capsule. SL-OCT allows precise anatomical localization of bleb pathology and in vivo imaging of the effect of needling on bleb function. .

## References

1. Dada T, Gadia R, Sharma A, Ichhpujani P, Bali SJ, Bhartiya S, Panda A. Ultrasound biomicroscopy in glaucoma. *Surv Ophthalmol*. 2011 Sep-Oct;56(5):433-50.
2. Pavlin CJ, Harasiewicz K, Foster FS. Ultrasound biomicroscopy of anterior segment structures in normal and glaucomatous eyes. *Am J Ophthalmol*. 1992; 113:381-389.
3. Radhakrishnan S, Rollins AM, Roth JE et al. Real-time optical coherence tomography of the anterior segment at 1310 nm. *Arch Ophthalmol*. 2001; 119(8):1179-85.
4. Dada T, Shah BM, Bali SJ, Bansal N, Panda A, Vanathi M. Anterior segment OCT imaging in opaque grafts with secondary glaucoma following tectonic penetrating keratoplasty for perforated corneal ulcers. *Eye (Lond)*. 2011 Nov;25(11):1522-4.
5. Dada T, Aggarwal A, Vanathi M, Gadia R, Panda A, Gupta V, Sihota R. Ultrasound biomicroscopy in opaque grafts with post-penetrating keratoplasty glaucoma. *Cornea*. 2008 May;27(4):402-5.
6. Dada T, Sihota R, Gadia R, Aggarwal A, Mandal S, Gupta V. Comparison of anterior segment optical coherence tomography and ultrasound biomicroscopy for assessment of the anterior segment. *J Cataract Refract Surg*. 2007 May;33(5):837-40.
7. Dada T, Vengayil S, Gadia R et al. Slit-lamp-optical coherence tomography-guided needling of failing filtering blebs. *Arch Ophthalmol*. 2008 Feb;126(2):284-6.

# SYSTEMIC EVALUATION IN GLAUCOMA PATIENTS

Glaucoma is a multifactorial, progressive chronic optic neuropathy<sup>1</sup> which may be associated with many systemic disorders. It is important for the ophthalmologist to be aware of these systemic conditions which can influence the course of glaucoma and have a critical bearing on the quality of life of the patient. In addition, the medications being taken for systemic diseases may interact with glaucoma medications and pose an additional risk during surgery (eg. Use of anti-coagulants during trabeculectomy). Some of the diseases with multi-organ involvement affecting the ocular system include : hypertension, cardiovascular disease, diabetes, thyroid disorders, electrolyte disturbances, depression and chronic diseases requiring cortico-steroid therapy.<sup>2</sup>

It is also essential to rule out **cross-reactivity and allergy** to specific classes of medications such as sulfa drugs and make specific queries regarding **pregnancy and lactation** before prescribing glaucoma medications. Systemic work up is a critical issue in patients with normal pressure glaucoma, where vascular factors may be predominantly involved in disease pathogenesis.

Systemic evaluation in glaucoma patients is thus essential, but unfortunately often ignored. This may at times lead to unwarranted consequences with **medico-legal implications**. Since the treatment for glaucomas as well as the associated systemic disease often entails life-long therapy, the chance for drug adverse effects increase as the patient ages and a constant vigilance has to be maintained to prevent health related adverse effects on the quality of life of the patient.

All glaucoma patients must have their **blood pressure and fasting blood sugar** checked before initiating glaucoma therapy. The relationship between POAG and low systolic/diastolic blood pressure has been distinctly proven by the Baltimore Eye study and the Barbados Eye study. Diastolic perfusion pressure (Diastolic BP minus IOP) has a proven inverse relation with POAG progression and it is important to note that the patient does not have **hypotensive episodes due to over-treatment of hypertension**. If the patient is being treated with systemic beta blockers, topical beta blockers should be avoided. Diabetes may be present in one-third of POAG patients and must be checked for. Topical beta blockers may mask the symptoms of hypoglycemia in a diabetic patient<sup>3</sup> and these patients have a poorer prognosis after filtering surgery.<sup>4</sup>

## INVESTIGATIONS IN PATIENTS WITH NTG/LTG

The term normal-tension glaucoma (NTG) or low-tension glaucoma (LTG) refers to typical glaucomatous optic disc cupping and visual field loss in eyes that do not have elevated IOPs (> 21 mmHg).<sup>5,6</sup> However, it has convincingly been shown that an IOP reduction of at least 30% is associated with protection of visual field and nerve status. The evidence, therefore, suggests that IOP in the high-normal range is a causative factor in NTG, although other factors are also involved. Drance and coworkers<sup>7,8</sup> described two forms of NTG: (a) a non-progressive form, which is usually associated with a transient episode of vascular shock, and (b) a more common progressive form, which is believed to result from chronic vascular insufficiency of the optic nerve head.

Systemic diseases associated with NTG are:

1. Migraine headache and Raynaud's phenomenon
2. Vasospasm
3. Vascular diseases- carotid artery, myocardial infarction, cholesterol, inflammation



4. Nocturnal hypotension
5. Vascular dysregulation
6. Autoimmunity
7. Shock syndromes
8. Anemias
9. Diabetes mellitus
10. Obstructive sleep apnoea syndrome

**Investigations required to unveil these factors are summarized below:**

1. **Twenty-four-hour BP monitoring:** Patients with NTG have significantly greater nocturnal blood pressure drops than healthy persons<sup>9</sup>, as well as elevated diastolic blood pressure<sup>10</sup>.
2. **Twenty-four-hour electrocardiographic monitoring:** There occurs significantly greater asymptomatic myocardial ischemia in patients with NTG (45%) than in healthy individuals (5%), especially during night<sup>11</sup>, signifying the importance of 24 hour electrocardiographic monitoring.
3. **Blood tests**
  - a. *Complete blood counts:* Anaemia, increased blood and plasma viscosity and hypercoagulability are found to be associated with NTG<sup>12</sup>.
  - b. *Blood lipid profile:* Hypercholesterolemia is reported to be higher among patients with NTG<sup>13</sup>.
  - c. *C-reactive protein:* a risk factor in acute vascular inflammatory processes is found raised in NTG<sup>21</sup>, linking it to a vascular etiology.
  - d. *Blood sugar-* Diabetes mellitus has been positively linked with NTG
  - e. *Auto-immune markers:* Checking for the presence of antinuclear antibody (ANA) is recommended to rule out collagen-vascular and autoimmune diseases. Screening for extractable nuclear antigens (ie, Ro, La, Sm) also is recommended to rule out autoimmune diseases<sup>26</sup>. Anticardiolipin antibody (ACA) testing should be performed, and an increased level is considered a risk factor for visual-field defect progression.
  - f. *Serum immunofixation for monoclonal gammopathy is indicated:* Approximately 10% of patients with normal tension glaucoma have monoclonal gammopathy (paraproteinemia), which represents a benign condition two thirds of the time<sup>27</sup>. However, lymphoproliferative disorders (ie, cancers) need to be ruled out by a hemato-oncology specialist if results from this test are positive.
  - g. *Thyroid Status:* Dysthyroid status either causes optic neuropathy mimicking glaucomatous damage or is a risk factor for glaucoma<sup>23,25</sup>.
4. **Polysomnography and other sleep studies:** Prevalence of sleep apnea is 25-50% in NTG patients<sup>14</sup>. Polysomnography reveal even higher prevalence (63%) of sleep apnea in this patient group<sup>15</sup>. Moreover, decreased RNFL thickness<sup>16</sup> and visual field defects<sup>17</sup> have been found in sleep apnea patients. Thus, sleep history and sleep studies are warranted in NTG.
5. **Ocular blood flow and Carotid Doppler studies:** Multiple studies have suggested a link between NTG and reduced ocular blood flow. In patients with symmetric normal-tension glaucoma, duplex sonography shows an elevated resistance in CRA and PCA<sup>18</sup>. This may be due to vasospastic phenomenon or decreased blood flow in the carotid artery<sup>19</sup>. Other reported findings are hemodynamic crises, reduced diastolic ophthalmodynamometry levels and ocular pulse amplitudes,

bilateral complete occlusion of the internal carotid artery with reversed ophthalmic artery flow, focal arteriolar narrowing around the optic nerve, and increased vascular resistance of the ophthalmic artery by colour Doppler analysis. Carotid Doppler studies should be performed in asymmetric NTG or in patients progressing despite IOP control<sup>20</sup>.

6. **Cardiovascular investigations:** NTG has been positively linked to atherosclerosis, cerebrovascular events secondary to atherosclerosis<sup>21</sup>, myocardial infarction, arrhythmias, transient ischemic attacks and acute shock like state<sup>22</sup>. This again confirms a vascular etiology. Brain MRI in these patients reveal diffuse ischaemic picture. Thus a complete evaluation of the cardiovascular system, including specialist evaluation, echo-cardiography, and stress tests should be performed. Anti-coagulants may have to be stopped before glaucoma surgery in consultation with the cardiologists.
7. **Neuroimaging and Neurological assessment:** MRI is the preferred imaging modality compared with CT scanning because of its higher sensitivity. Controversy exists as to whether neuroimaging should be performed routinely. Some advocate referral to a neuroophthalmologist if concerned. Neuroimaging is indicated in disc pallor more than cupping, young patients, progressive field loss despite equal IOPs, visual field defect not respecting horizontal midline, unilateral or asymmetric dyschromatopsia, rapid progression of visual fields, rapid progression of optic neuropathies, afferent pupillary defect with mild cupping and associated ocular motility defects<sup>24</sup>.
9. **Genetic analysis:** Genetic heterogeneity is the hallmark of all glaucomas and multiple chromosomal loci have been linked to the disease. Optineurin gene has been linked to NTG and has been hypothesised to play a role in both NTG and Alzheimer's disease giving rise to a neurodegenerative process in the etiology of NTG<sup>28</sup>. Interestingly Helicobacter pylori has been found as a possible common underlying risk factor for Normal-tension glaucoma and Alzheimer's disease<sup>30</sup>. Examinations of retinal vasculature may provide clue to this linkage<sup>31</sup>. The OPA1 polymorphism is associated with NTG, and may be used as a marker for this disease association<sup>29</sup>. This has led some researchers to believe that normal tension glaucoma may actually be a hereditary optic neuropathy with a pathophysiology based in mitochondrial dysfunction<sup>32</sup>.

### SYSTEMIC INVESTIGATIONS BEFORE GLAUCOMA SURGERY

Glaucoma surgery is most commonly undertaken under local anaesthesia. The aim of the pre-operative assessment is to obtain the relevant medical and social information about the patient, to educate the patient and diminish anxiety, and to obtain informed consent for the operative procedure<sup>33</sup>. Factors considered in investigating patients undergoing surgery include

1. Detecting conditions not found on history and examination that will affect peri-operative management;
2. Detecting systemic conditions that will increase risk of complications;
3. Medico-legal considerations, and
4. An opportunity to screen for medical problems<sup>34</sup>.

Traditionally, routine investigations prior to surgery are considered an important element of pre-anesthetic evaluation to determine the fitness for anaesthesia and surgery<sup>35</sup>. Many hospitals have rather arbitrary rules to perform a series of laboratory tests prior to any operative procedure with the assumption that voluminous information would enhance the safety of surgical patients and reduce the liability for adverse events<sup>36,37</sup>.

The value of performing routine investigations in all patients undergoing surgery has been questioned by many well conducted studies, and this practice is currently not recommended. Revised guidelines, now emphasises on preoperative testing in the presence of specific clinical characteristics<sup>38</sup>.

### Guidelines for preoperative testing

1. **Electrocardiogram:** Clinical characteristics are Cardio circulatory disease and respiratory disease. Age alone may not be an indication for an electrocardiogram; however, no consensus for specific minimum age for ECG is given.
2. **Pre anaesthesia Chest Radiographs (X-ray):** Clinical characteristics to consider chest X-ray include smoking, recent upper respiratory infection, chronic obstructive pulmonary disease (COPD), and cardiac disease. However these are not to be considered unequivocal indications for chest radiography.
3. **Pre anaesthesia haemoglobin or haematocrit:** Routine haemoglobin or haematocrit is not indicated. Clinical characteristics to consider include patients with liver disease, extremes of age, history of anaemia, bleeding, and other hematologic disorders.
4. **Pre anaesthesia serum chemistry** (i.e., Potassium, Glucose, Sodium, Renal and Liver Function Studies). Clinical characteristics to consider before ordering such tests include likely perioperative therapies, endocrine disorders, risk of renal and liver dysfunction, and use of certain medications or alternative therapies.
5. **Pre anaesthesia urinalysis:** Routine urinalysis is not indicated except when urinary tract symptoms are present.
6. **Coagulation profile:** This includes testing for PT, PTT, INR and Platelet count. Blood testing for this parameter is recommended in following situations-
  - Where history suggests risk of haemorrhage
  - Patient is on anti-coagulant treatment
  - Anaemic patients
  - Patients with history of excessive bleeding after a prior surgery
  - Drinkers of more than 500ml wine per day<sup>39</sup>

Clinical characteristics to consider for ordering selected coagulation studies include bleeding disorders, renal dysfunction, liver dysfunction, and type and invasiveness of procedure, anticoagulant medications and alternative therapies<sup>38</sup>.

Although glaucoma surgery in healthy patients does not fit into any of these categories, still intra-operative haemorrhage can alter the outcome of surgery<sup>40</sup>. Thrombocytopenia, which may or may not be suspected by a routine questionnaire, is a significant risk factor for perioperative bleeding in ocular surgery<sup>40</sup>. Therefore it may be prudent to include coagulation profile for all patients undergoing glaucoma surgery.

7. **Preanaesthesia Pregnancy Testing:** Pregnancy testing is recommended for all female patients of childbearing age.

**Timing of pre-operative testing:** Test results obtained from the medical record within 6 months of surgery are generally acceptable if the patient's medical history has not changed substantially. More recent test results may be desirable when the medical history has changed, or when test results may play a role in the selection of a specific anaesthetic technique (e.g., in the setting of anticoagulation therapy)<sup>38</sup>

### SUMMARY

The systemic investigations required in patients with POAG, NTG and before glaucoma surgery are summarised in Table 1.



INVESTIGATION	POAG	NTG	BEFORE GLAUCOMA SURGERY
BP Monitoring	Continued progression despite adequate IOP control	24 hour BP monitoring in all patients	All patients
ECG monitoring	Exfoliative Glaucoma, History suggestive of cardiopulmonary disease	24 hour ECG monitoring in all patients	Cardio-respiratory diseases
Complete blood count	Based on physical examination	All patients	Liver disease, anaemia, extremes of age, bleeding
Cardiovascular investigations (echo, stress test, cardiologist)	Some cases (see NTG), Exfoliative Glaucoma	Atherosclerosis, myocardial infarction, arrhythmias, transient ischemic attacks and acute shock like state	If clinically appropriate
Ocular blood flow studies	Some atypical cases	Suspected carotid artery disease	Usually not required
Polysomnography and sleep studies	Suggestive history present	Obstructive sleep apnea	Usually not required
Blood sugar	All cases	All cases	Selected cases(see text)
Coagulation profile	Not required	History of episodes of acute hemorrhage	All glaucoma patients
Blood lipid	Not required	Hypercholesterolemia	Selected cases(see text)
Chest x ray	Not required	Sarcoidosis, Cardio-respiratory diseases	COPD, Cardiac disease, smoking, recent URI
Urinalysis	Not required	Not required	Urinary tract symptoms
Cold challenge- nail bed capillaroscopy	Migraine like headaches, Raynaud's phenomenon	Migraine like headaches, Raynaud's phenomenon (more frequent than in POAG)	Not required
Inflammatory markers( CRP, ANA, ANCA, RF, ESR)	Usually not required	Collagen vascular and autoimmune diseases( eg. SLE)	Suspicion of inflammatory disorder
Serum immunofixation	Not required	Monoclonal gammopathy	Not required
Thyroid profile	Clinical suggestion	Dysthyroid status	Clinical suspicion
Neurological studies	Atypical cases(see NTG)	Disc pallor more than cupping, young patients, progressive field loss despite equal IOPs, visual field defect not respecting horizontal midline, unilateral dyschromatopsia, rapid progression ,afferent pupillary defect with mild cupping , ocular motility defects, acute shock like state	Usually not required
Pregnancy	Before prescribing contraindicate drugs, if appropriate	Before prescribing contraindicate drugs , if appropriate	Females of child bearing age
Genetic testing	Young patients	Associated Alzheimer's disease, progression despite IOP control Progression unrelated to IOP	Not required

Table 1.Summary of systemic investigations required in patients with glaucoma

## References

1. American Academy of Ophthalmology Glaucoma Panel. Preferred Practice Pattern® Guidelines. Primary Open-Angle Glaucoma. San Francisco, CA: American Academy of Ophthalmology; 2010.
2. Herng-Ching Lin, Ching-Wen Chien, Chao-Chien Hu, Jau-Der Ho. Comparison of co morbid conditions between open angle glaucoma patients and a control cohort. A case control study. *Ophthalmology*. 2010; 117 (11) :2088-95
3. Velde TM, Kaiser FE. Ophthalmic timolol treatment causing altered hypoglycemic response in a diabetic patient. *Arch Internal Med*. 1983;143-62.
4. Broadway DC, Grierson I, O'Brien C, Hitchings RA. Adverse effects of topical antiglaucoma medication. II. The outcome of filtration surgery. *Arch Ophthalmol*. 1994 Nov;112(11):1446-54
5. Shields MB. Normal-tension glaucoma: is it different from primary open-angle glaucoma? *Curr Opin Ophthalmol*. 2008;19(2):85-88
6. Greenfield DS, Liebmann JM, Ritch R, et al. Visual field and intraocular pressure asymmetry in the low-pressure glaucoma treatment study. *Ophthalmology*. 2007;114(3):460-65
7. Drance SM, Sweeney VP, Morgan RW, et al. Studies of factors involved in the production of low tension glaucoma. *Arch Ophthalmol*. 1973;89(6):457-65.
8. Drance SM, Morgan RW, Sweeney VP. Shock-induced optic neuropathy: a cause of nonprogressive glaucoma. *N Engl J Med*. 1973;288(8): 392-95.
9. Meyer JH, Brandi-Dohrn J, Funk J. Twenty four hour blood pressure monitoring in normal tension glaucoma. *Br J Ophthalmol*. 1996; 80(10):864-67.
10. Hulsman CA, Vingerling JR, Hofman A, et al. Blood pressure, arterial stiffness, and open-angle glaucoma: the Rotterdam study. *Arch Ophthalmol*. 2007;125(6):805-12.
11. Waldmann E, Gasser P, Dubler B, et al. Silent myocardial ischemia in glaucoma and cataract patients. *Graefes Arch Clin Exp Ophthalmol*. 1996;234(10):595-98.
12. Klaver JH, Greve EL, Goslinga H, et al. Blood and plasma viscosity measurements in patients with glaucoma. *Br J Ophthalmol*. 1985; 69(10):765-770.
13. Winder AF. Circulating lipoprotein and blood glucose levels in association with low-tension and chronic simple glaucoma. *Br J Ophthalmol*. 1977;61(10):641-45.
14. Sleep disorders: a risk factor for normal tension glaucoma?. Marcus DM, Costarides AP, Gokhale P et al. *J Glaucoma*. 2001;10:177-83.
15. Normal-tension glaucoma is associated with sleep apnea syndrome. Mojon DS, Hess CW, Goldblum D et al. *Ophthalmologica*. 2002; 216:180-84.
16. Retinal nerve fibre layer measurements are reduced in patients with obstructive sleep apnea syndrome. Kargi SH, Altin R, Koksai M et al. *Eye*. 2005;19:575-79.
17. Moderate to severe obstructive sleep apnoea patients associated with a higher incidence of visual field defects. Tsang CS, Chong SL, Ho DK, et al. *Eye*. 2006;20:38-42.
18. Duplex sonography of retro-orbital and carotid arteries in patients with normal-tension glaucoma. Akcar N, Yildirim N, Adapinar B, Kaya T, Ozkan IR. *J Clin Ultrasound*. 2005 Jul-Aug;33(6):270-6.
19. An ultrasonic vascular examination using continuous Doppler emission in normal-tension glaucoma. Mocanu C. *Oftalmologia*. 1998;42(1):20-4.
20. Relationship between cefalo-ophthalmic haemodynamics and visual function in patients affected by carotid stenosis. Possible links with critical low tension glaucoma pictures. Vitale Brovarone F, Fea A, Rabbia C, et al. *Acta Ophthalmol Scand Suppl*. 1998;(227):45-6.
21. Is symptomatic atherosclerotic cerebrovascular disease a risk factor for normal-tension glaucoma?. Güngör IU, Güngör L, Ozarslan Y. *Med Princ Pract*. 2011;20(3):220-4.
22. Magnetic resonance imaging in patients with low-tension glaucoma. Stroman GA, Stewart WC, Golnik KC, et al. *Arch Ophthalmol*. 1995;113(2): 168-72.
23. Thyroid disease, a risk factor for optic neuropathy mimicking normal-tension glaucoma. Jämsén K. *Acta Ophthalmol Scand*. 1996 Oct;74(5):456-60.
24. Nonglaucomatous cupping of the optic disc. Ambati BK, Rizzo JF 3rd. *Int Ophthalmol Clin*. 2001 Winter;41(1):139-49.
25. Dysthyroid optic neuropathy (DON). Ebner R. *Semin Ophthalmol*. 2002 Mar;17(1):18-21.
26. Anti-Ro/SS-A positivity and heat shock protein antibodies in patients with normal-pressure glaucoma. Wax MB, Tezel G, Saito I, et al. *Am J Ophthalmol*. 1998;125(2):145-57
27. Increased incidence of paraproteinemia and autoantibodies in patients with normal-pressure glaucoma. Wax MB, Barrett DA, Pestronk A. *Am J Ophthalmol*. 1994;117(5):561-8.
28. Hypothesis of optineurin as a new common risk factor in normal-tension glaucoma and Alzheimer's disease. Liu YH, Tian T. *Med Hypotheses*. 2011 Oct;77(4):591-2. Epub 2011 Jul 18.
29. The OPA1 gene polymorphism is associated with normal tension and high tension glaucoma. Mabuchi F, Tang S, Kashiwagi K, Yamagata Z. *Am J Ophthalmol*. 2007 Jan;143(1):125-30.
30. Normal-tension glaucoma and Alzheimer's disease: Helicobacter pylori as a possible common underlying risk factor. Kountouras J, Zavos C, Gavalas E. *Med Hypotheses*. 2007;68(1):228-9. Epub 2006 Sep 15.
31. Normal-tension glaucoma and Alzheimer's disease: retinal vessel signs as a possible common underlying risk factor. Tian T, Liu YH. *Med Hypotheses*. 2011 Sep;77(3):466.
32. Is normal tension glaucoma actually an unrecognized hereditary optic neuropathy? New evidence from genetic analysis. Buono LM, Foroozan R, Sergott RC, Savino PJ. *Curr Opin Ophthalmol*. 2002 Dec;13(6):362-70
33. The pre-operative assessment and investigation of ophthalmic patients. McKibbin M. *Eye (Lond)*. 1996;10 ( Pt 1):138-40.
34. Pre-operative patient assessment: a review of the literature and recommendations. Barnard NA, Williams RW, Spencer EM. *Ann R Coll Surg Engl*. 1994;76:293-7.
35. Role of routine laboratory investigations in preoperative evaluation. Kumar A, Srivastava U. *J Anaesthesiol Clin Pharmacol*. 2011 Apr-Jun; 27(2): 174-9
36. Roizen MF, Lichter JL. Preoperative assessment and premedication for adults. In: Healy TEJ, Knight PR, editors. 7th ed. *Wylie and Churchill Davidson's A practice of Anesthesia*; 2003. pp. 415-25
37. Pre-operative testing. *Curr Anesth Reports*. Badar AM. 2001;1:67-9..
38. Practice Advisory for Preanesthesia Evaluation. A Report by the American Society of Anesthesiologists Task Force on Preanesthesia Evaluation. *Anesthesiology* 2002; 96:485-96.
39. Anticoagulation therapy in glaucoma surgery. Alwitry A, King AJ, Vernon SA. *Graefes Arch Clin Exp Ophthalmol*. 2008 Jun;246(6):891-6.
40. Thrombocytopenia and the risks of intraocular surgery. Papamatheakis DG, Demers P, Vachon A, Jaimes LB, Lapointe Y, Harasymowycz PJ. *Ophthalmic Surg Lasers Imaging*. 2005 Mar-Apr;36(2):103-7.

# ROLE OF TECHNOLOGY IN THE DIAGNOSIS OF GLAUCOMA & ASSESSING ITS PROGRESSION

Glaucoma is the second leading cause of blindness worldwide.<sup>1</sup> As clinicians, we not only owe the best possible care to the patients who seek medical help, but also a responsibility towards those undetected and improperly treated. The current status of glaucoma care in the world is aptly summarized as follows: more than 50% of glaucoma in the community is undiagnosed (in the developing countries this would be higher than 90%),<sup>2</sup> more than 50% of those undiagnosed would have seen an eye care provider in the recent past, more than 50% taking medications do not need them (over treated)<sup>3</sup> and finally 50% of those advised medication do not use them. Missed diagnoses in those previously examined by an eye care professional, (in the “system”) is attributable to lack of comprehensive evaluation and appropriate clinical skills.<sup>4</sup> The recent advances in the imaging of the optic nerve head seek to achieve an early and “objective” diagnosis of glaucoma. One of the reasons for over diagnosis is using the results of these technologies exclusively and not in the context of complete clinical picture.<sup>5</sup>

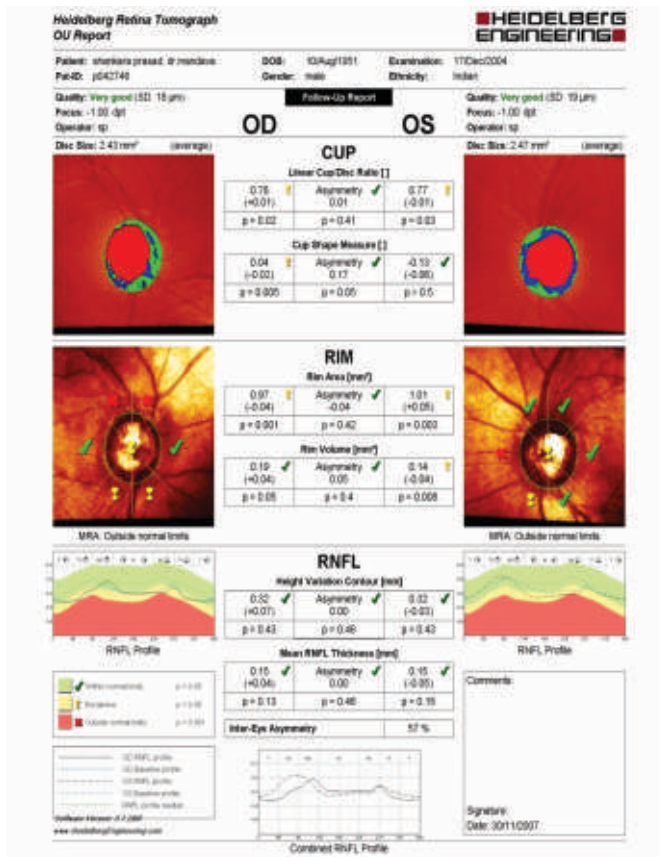
## Diagnosis:

Imaging of the optic nerve head and retinal nerve fiber layer are widely reported to be useful in glaucoma diagnosis. One could (naively) argue that the imaging tests are objective and can be performed easily in uncooperative patients (since they are quick and need little attention) as opposed to standard automated perimetry (SAP), which is the current standard but time consuming and difficult due to the subjective nature of the test. Further, as it is reported that 20 - 40% retinal ganglion cells could be lost before a visual field defect could be picked up by SAP, these imaging technologies can theoretically aid in the early diagnosis of glaucoma. This rationale need not necessarily convert to a clinical reality. Figures 1-5 show a glaucoma suspect (because of positive family history and suspicious optic disc) followed up for a decade. All the three glaucoma imaging technologies showed an “abnormality”, but the SAP result was always normal. Why does this happen? The reported sensitivity and specificity of these technologies and their agreement with each other are far from ideal.<sup>6</sup> The sensitivity (ability to diagnose the disease correctly – PID: positive in disease) of the best parameter for each of the imaging technologies at a fixed specificity (NIH: negative in health or ability to declare a normal subject as not having the disease) of 95% (labeling only 5 as abnormal out of hundred normal subjects) varies from 36 to 72%. This means that the imaging technologies fail to diagnose glaucoma in as many as 28% to 64% of the eyes with established abnormality on SAP. While we perform these investigations with the idea of either establishing or ruling out a disease, we fail to realize that there is a cost benefit ratio even in diagnostic testing. These tests are expensive, there are risks of over diagnosis with the attendant effect of labeling and there are problems with interpretation (the normative data base of the machine used for diagnostic classification is often limited to small number of subjects and few ethnicities and hence may not be appropriate to apply for testing patients of all ethnicities). We have reported that the incorporation of the Indian normative data base, does not improve the diagnostic ability of HRT 3.<sup>7</sup>

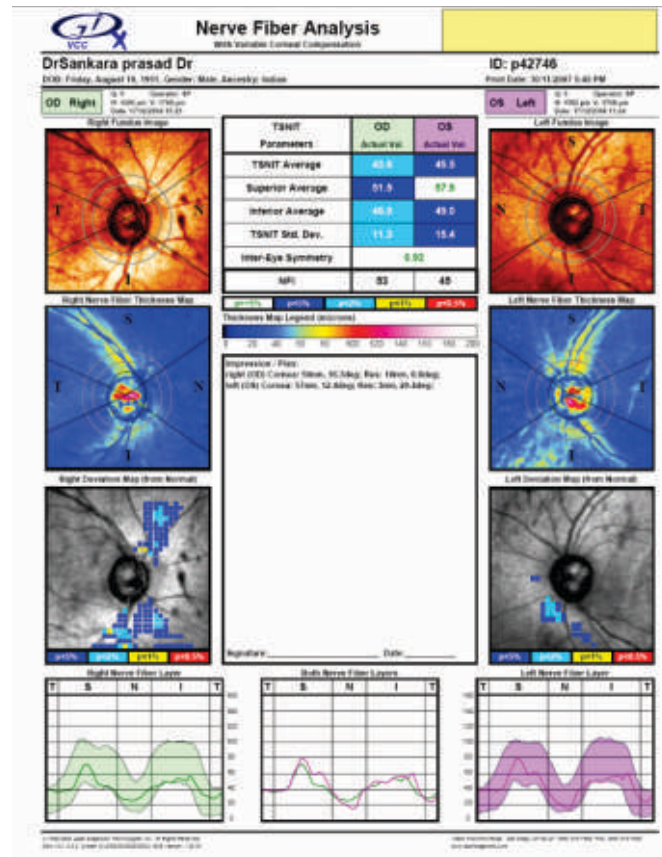
In addition to the above limitations, bias in the ability of imaging devices to diagnose glaucoma can arise from multiple other sources. Optic disc size has been shown to be a confounder in the diagnostic accuracy of HRT.<sup>8-9</sup> Delineation of the optic disc margin and measurement circle placement have been shown to be confounders in the diagnostic ability of these instruments.<sup>10</sup> Reporting the diagnostic ability in glaucoma patients while using a set of totally normal subjects as controls, also is shown to artifactually inflate the sensitivity of these instruments.<sup>11</sup> This is because a diagnostic test in clinical practice is used in situations which arouse a suspicion of the disease and not in situations where the diagnosis of a disease is easy to either rule in or rule out by clinical examination.



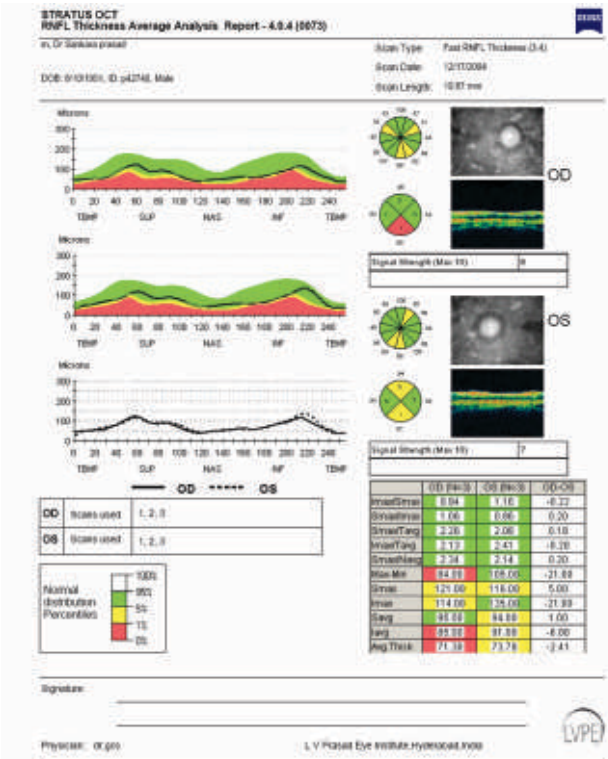
# DIAGNOSIS OF GLAUCOMA & ASSESSING ITS PROGRESSION



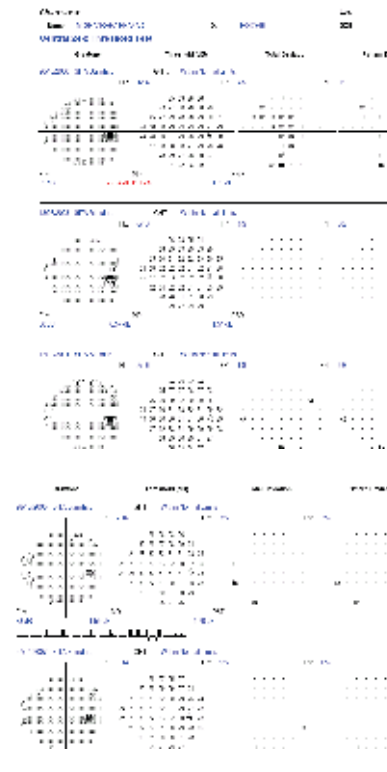
1. HRT showing abnormal result in both the eyes.



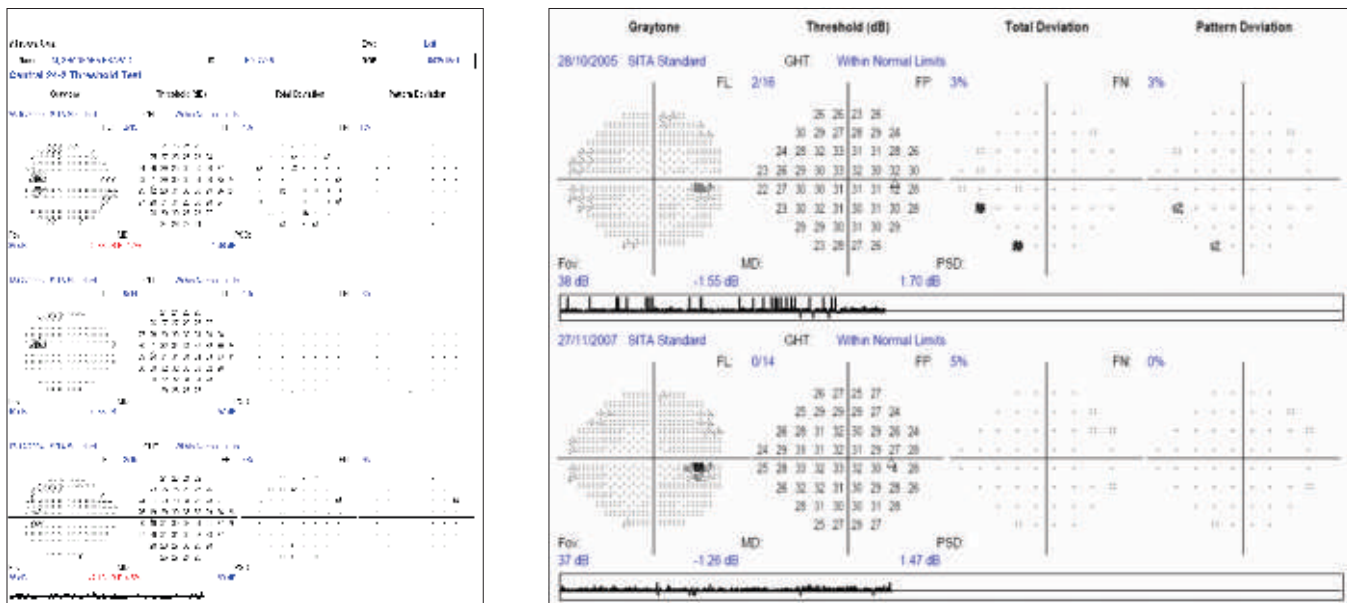
2. GDx showing abnormal result in both the eyes.



3. OCT showing abnormal result in both the eyes.



4. Normal visual fields of the right eye




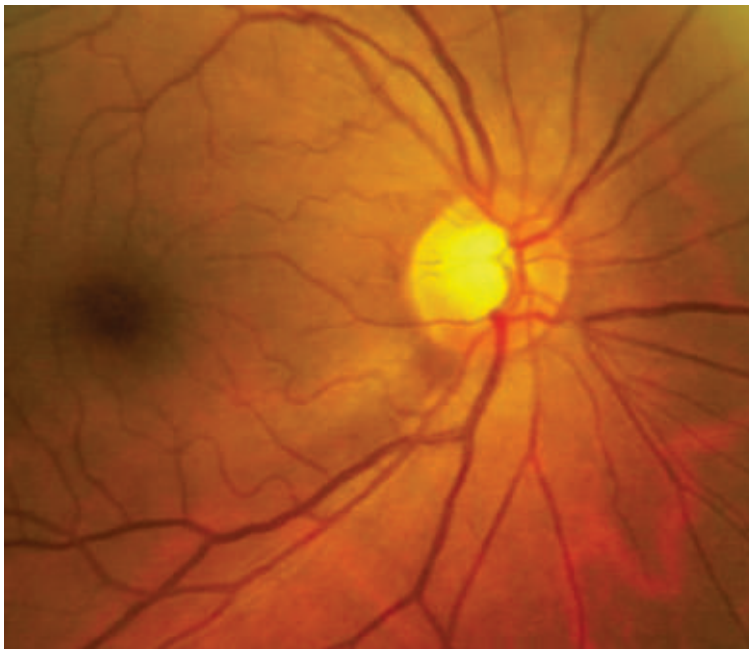
5. Normal visual fields of the left eye

Garway- Heath appropriately stated that “devices cannot diagnose our patients' conditions, but the findings they provide frequently alter the probability that a subject has a particular condition”.<sup>5</sup> Thus devices cannot be a substitute for poor clinical skills but at best a complement to good clinical evaluation. If after a good and comprehensive clinical evaluation the probability (pre-test probability) of the disease is around 20%, it is futile to perform any diagnostic test, as even a positive result cannot confirm the presence of the disease. On the other hand if the probability of the disease is about 80% after a good clinical examination (the need for testing is not to diagnose but probably to establish a base line for follow up), even a negative test result cannot rule out the disease. It is in the intermediate range, when the probability of disease is around 50% that the diagnostic test result would strongly help in the diagnostic decision. Before ordering a diagnostic test, it is useful to ask ourselves as to how our course of action would change based on the test result. The probability of the disease before and after the diagnostic test can be mathematically calculated using the likelihood ratio (LR) of the test result in consideration. If we want to use the results of the diagnostic tests appropriately, estimating the LR is the best way around. Thus it is important for us to know the LRs associated with different test results before investing in a new diagnostic test.

The principle behind the use of the likelihood ratios is the calculation of the increase in the probability of a given diagnosis given the prior probability of the disease (based on complete clinical evaluation or the prevalence of the disease) and the result of the diagnostic test with its likelihood ratio. This principle is applicable not only for the diagnosis of a disease but also for any event. This principle in mathematical terms is called the Bayesian theorem. Keeping the mathematics aside, the concept is very intuitive and we keep using this in our daily lives extensively, albeit without the mathematical calculations or the complex terminologies.

For example, on a cloudy day during the rainy season, if it rains we say “it is bound to happen” and if it did not rain, one might say “that was very unlikely” or some such thing. If a 25 year old healthy, prospective, army recruit ends up with an ST segment change on ECG, one would suspect the test or the machine, as the likelihood of this young, healthy man having ischemic heart disease (IHD) is very low. The same result in a 60 year old gentleman with diabetes and hypertension with pre-cordial discomfort on exertion would be diagnostic of IHD. The prior probability of IHD is very high in the latter and very low in the former. This explains why the same test





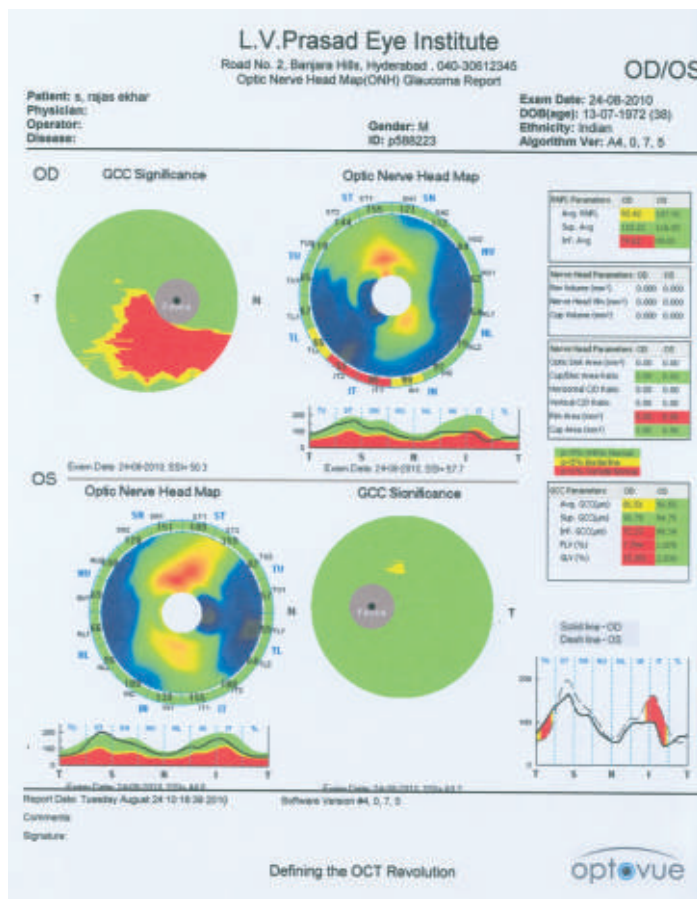
6. Disc image showing inferior NFL defect and normal visual field.

result is interpreted differently in different situations. The clinical use of the LR is exemplified in figs 6-8. The suspicious disc with an inferior NFL defect on disc photograph as well as the opticle coherence tomography (fig 6, 7) and a normal visual field leads us to a prior probability of having glaucoma to be 60%. Fig 8 show the calculations for the post test probability for glaucoma diagnosis, which works out to be 98%.

## Progression:

Halting progression of glaucomatous damage during the life time of the patient, with minimum effect on the quality of life, is one of the main objectives of any glaucoma treatment. But judging glaucoma progression is a challenging task. Progression of glaucoma is known to occur at variable pace. The untreated arm of the Early manifest glaucoma treatment (EMGT) trial is great source information of the natural history of glaucoma. It was found in the EMGT trial, that untreated normal tension glaucoma in the younger age group had the least rate of progression (never progressing to blindness from normal vision) and pseudo-exfoliation glaucoma in the elderly group could progress to blindness from normal vision in as little as 2 years.<sup>12</sup>

The standard method to detect glaucoma progression is to monitor the visual field (VF) defects periodically for change. Two commonly used approaches to detect change in VF defects over time are the event-based and the trend-based progression analyses. Event-based analysis determines VF progression to be either present or absent depending on a predefined change in the VF parameters. Trend-based analysis provides the actual rate of change of VF parameters. In clinical practice, information from both these analyses is important because it is not only sufficient to identify VF progression in glaucoma but also to determine the rate of progression, so that the treatment can be more aggressive in patients that progress rapidly. The recently introduced Guided Progression Analysis by the Humphrey VF Analyzer (Carl Zeiss Meditec, Inc. Dublin, CA) provides both an event-based progression analysis and a trend-based analysis on the same printout. The event-based progression analysis, called the glaucoma progression analysis (GPA) is based on the criteria designed to identify VF progression in the Early Manifest Glaucoma Trial.<sup>13</sup> Trend-based progression analysis is based on the rate of progression (ROP) of the visual function of the eye through a linear regression model using a new global index, Visual Field Index (VFI).<sup>14</sup> The VFI is the aggregate percentage of visual function for a given field at each point



7. OCT showing inferior NFL loss.

## Clinical Utility: Likelihood Ratio

**Disease probability of 0.70 and LR of 12.4**

- Pre-test odds = pre test probability / 1 - pre test probability  
= 0.7 / 0.3 = 2.3
- Pre Test Odds \* LR = Post Test odds
- Post-test odds = 2.3 \* 12.4 = 28.5
- Post-test probability = post test odds / post test odds + 1  
= 28.5 / 29.5 = 0.97 = 97%

8. Calculation of the post test probability using the likelihood ratio of inferior average thickness of OCT.

where the visual thresholds are estimated. VFI is calculated from pattern deviations in eyes with a mean deviation (MD) of better than -20 dB and from total deviations in eyes with a MD worse than -20 dB. The central points have more weight than peripheral points. VFI is also shown to be less affected by media opacities like cataract.<sup>15</sup>

Though most of the imaging technologies have both event and trend based algorithms to judge structural progression in glaucoma, their usefulness needs to be validated and there is no consensus on what constitutes a significant structural change clinically. HRT Topographic Change Analysis (TCA) is the most well developed and tested progression detection analysis available for optical imaging techniques. Glaucoma progression algorithms on GDx are called GDx GPA. Time domain OCT also has progression analysis of the RNFL parameters. The agreement between the structural changes of these imaging technologies and the visual field parameters have been reported to be moderate to poor.<sup>16-22</sup> Longitudinal data of the anatomical changes on the imaging technologies subsequently converting to field changes is available only for HRT from the OHTS.<sup>23</sup> We believe that the gold standard for assessing glaucoma progression continues to be the standard automated perimetry.

In conclusion, in establishing the diagnosis and progression of glaucoma, advances in the imaging technologies of the optic nerve are a complement to a good and comprehensive clinical evaluation and cannot be a substitute. The results of these tests need to be interpreted in the context of the remaining clinical picture and not in isolation.



## References

1. Quigley HA, Broman AT. The number of people with glaucoma worldwide in 2010 and 2020. *Br J Ophthalmol* 2006;90:262-7.
2. Vijaya L, George R, Arvind H, et al. Prevalence of angle-closure disease in a rural southern Indian population. *Arch Ophthalmol* 2006;124:403-9.
3. Vaahtoranta-Lehtonen H, Tuulonen A, Aronen P, et al. Cost effectiveness and cost utility of an organized screening programme for glaucoma. *Acta Ophthalmol Scand* 2007;85:508-18.
4. Thomas R, Dogra M. An evaluation of medical college departments of ophthalmology in India and change following provision of modern instrumentation and training. *Indian J Ophthalmol* 2008;56:9-16.
5. Garway-Heath DF, Friedman DS. How should results from clinical tests be integrated into the diagnostic process? *Ophthalmology* 2006;113:1479-80.
6. Kanamori A, Nagai-Kusuhara A, Escano MF, Maeda H, Nakamura M, Negi A. Comparison of confocal scanning laser ophthalmoscopy, scanning laser polarimetry and optical coherence tomography to discriminate ocular hypertension and glaucoma at an early stage. *Graefes Arch Clin Exp Ophthalmol* 2006;244:58-68.
7. Rao HL, Babu GJ, Sekhar GC. Comparison of the diagnostic capability of the Heidelberg Retina Tomographs 2 and 3 for glaucoma in the Indian population. *Ophthalmology* 2010;117:275-81.
8. Medeiros FA, Zangwill LM, Bowd C, Sample PA, Weinreb RN. Influence of disease severity and optic disc size on the diagnostic performance of imaging instruments in glaucoma. *Invest Ophthalmol Vis Sci* 2006;47:1008-15.
9. Garudadri CS, Rao HL, Parikh RS, et al. Effect of Optic Disc Size and Disease Severity on the Diagnostic Capability of Glaucoma Imaging Technologies in an Indian Population. *J Glaucoma* 2011.
10. Gabriele ML, Ishikawa H, Wollstein G, et al. Optical coherence tomography scan circle location and mean retinal nerve fiber layer measurement variability. *Invest Ophthalmol Vis Sci* 2008;49:2315-21.
11. Medeiros FA, Ng D, Zangwill LM, Sample PA, Bowd C, Weinreb RN. The effects of study design and spectrum bias on the evaluation of diagnostic accuracy of confocal scanning laser ophthalmoscopy in glaucoma. *Invest Ophthalmol Vis Sci* 2007;48:214-22.
12. Heijl A, Bengtsson B, Hyman L, Leske MC. Natural history of open-angle glaucoma. *Ophthalmology* 2009;116:2271-6.
13. Leske MC, Heijl A, Hyman L, Bengtsson B. Early Manifest Glaucoma Trial: design and baseline data. *Ophthalmology* 1999;106:2144-53.
14. Bengtsson B, Heijl A. A visual field index for calculation of glaucoma rate of progression. *Am J Ophthalmol* 2008;145:343-53.
15. Rao HL, Jonnadula GB, Addepalli UK, Senthil S, Garudadri CS. Effect of Cataract Extraction on Visual Field Index in Glaucoma. *J Glaucoma* 2011.
16. Chauhan BC, Nicolela MT, Artes PH. Incidence and Rate of Glaucomatous Visual Field Progression After Optic Disc Change Measured With Scanning Laser Tomography [ARVO abstract]. *Invest Ophthalmol Vis Sci* 2009;50:E-Abstract 2574.
17. Chauhan BC, McCormick TA, Nicolela MT, LeBlanc RP. Optic disc and visual field changes in a prospective longitudinal study of patients with glaucoma: comparison of scanning laser tomography with conventional perimetry and optic disc photography. *Arch Ophthalmol* 2001;119:1492-9.
18. Bowd C, Balasubramanian M, Weinreb RN, et al. Performance of confocal scanning laser tomograph Topographic Change Analysis (TCA) for assessing glaucomatous progression. *Invest Ophthalmol Vis Sci* 2009;50:691-701.
19. O'Leary N, Crabb DP, Mansberger SL, et al. Glaucomatous progression in series of stereoscopic photographs and Heidelberg retina tomograph images. *Arch Ophthalmol* 2010;128:560-8.
20. Alencar LM, Zangwill LM, Weinreb RN, et al. Agreement for detecting glaucoma progression with the GDx guided progression analysis, automated perimetry, and optic disc photography. *Ophthalmology* 2010;117:462-70.
21. Grewal DS, Sehi M, Greenfield DS. Comparing rates of retinal nerve fibre layer loss with GDxECC using different methods of visual-field progression. *Br J Ophthalmol* 2010.
22. Leung CK, Cheung CY, Weinreb RN, et al. Evaluation of retinal nerve fiber layer progression in glaucoma: a study on optical coherence tomography guided progression analysis. *Invest Ophthalmol Vis Sci* 2010;51:217-22.
23. Weinreb RN, Zangwill LM, Jain S, et al. Predicting the onset of glaucoma: the confocal scanning laser ophthalmoscopy ancillary study to the Ocular Hypertension Treatment Study. *Ophthalmology* 2010;117:1674-83.

# DORZOX

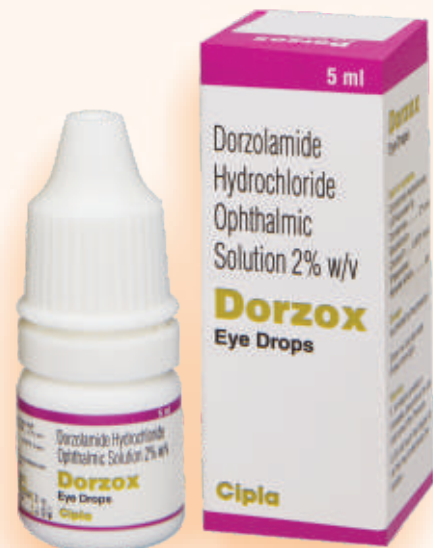Dorzolamide 2% **EYE DROPS**

**8** *Successful  
Years of IOP  
Control and  
Vasoprotection*

Ref :

1. Am J Ophthalmol 2002; 836-837

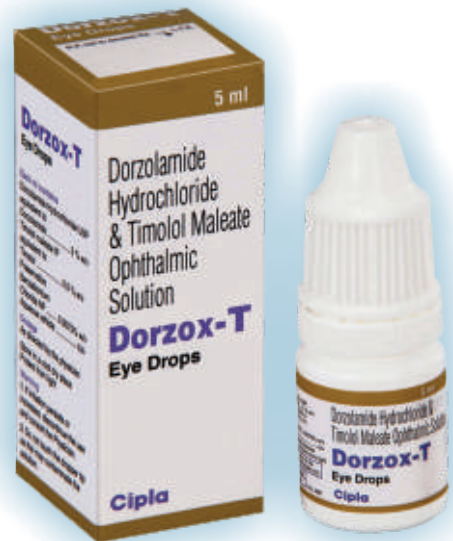**Cipla**



**The ideal adjunct  
proven in practice<sup>1</sup>**



**- Ensure increased patient  
convenience  
and  
compliance<sup>1</sup>**



**Cipla**  
**FORESIGHT™**

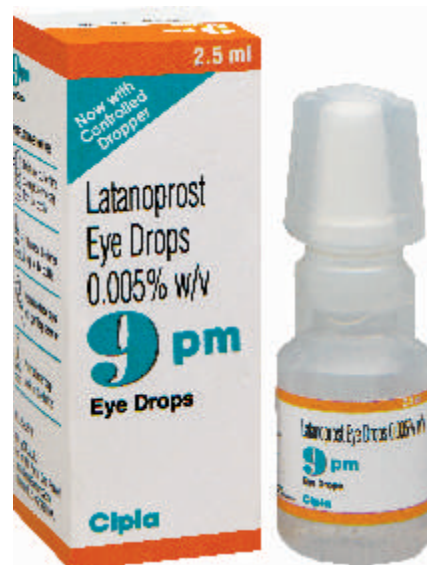Ref :1. Am. J. Ophthalmol 2000; 130: 832-833



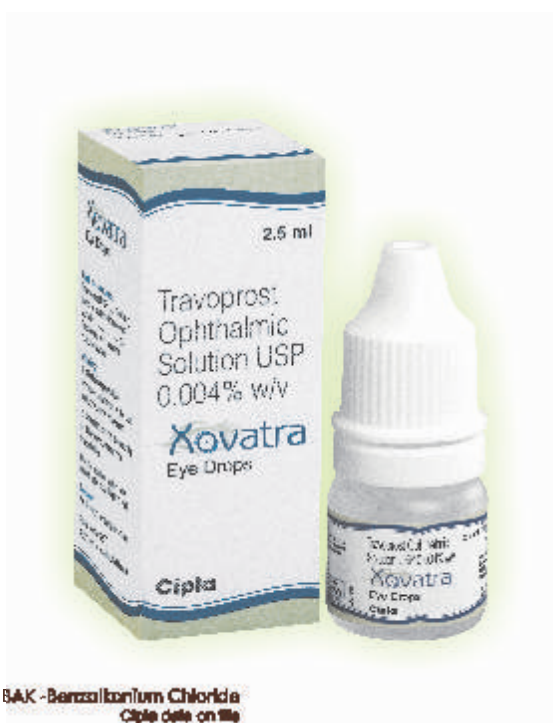**Cipla**

pm to pm  
IOP control

Now with  
**Controlled Dropper**



**Unique Patient Friendly Pack Insert**



\* BAK - Benzalkonium Chloride  
Cipla data on file

**Xovatra**

Eye Drops

Travoprost 0.004% w/v

**Xtended control with Xtra safety**

A New, Safer,  
**BAK\*** free ERA in  
the Medical  
Management  
of Glaucoma





## Terms of Use

Aim of these guidelines is to assist the Ophthalmologist in the Diagnosis & Management of Glaucoma Patients.

These guidelines are mere suggestions and cannot be used in court of law to safe guard against or for any legal proceedings. AIOS has no financial or any other interest in formulation of these guidelines.

***Joint initiative of***  
**All India Ophthalmological Society (AIOS)**  
**&**  
**Cipla**

